ANKARA MEME HASTALIKLARI DERNEĞİ BİLİMSEL TOPLANTISI

27.11.2014

www.fppt.info

GEBELİK VE LAKTASYON DÖNEMİNDE MEME KANSERİ

Dr.Pınar Uyar Göçün
Gazi Üniversitesi Tıp Fakültesi
Tıbbi Patoloji AD

www.fppt.info

- 41 y, kadın
- Sağ memeden stereotaktik vakumlu kor biyopsi
- 1.7 cm – 0.2 cm uzunluklarda 10 adet doku.

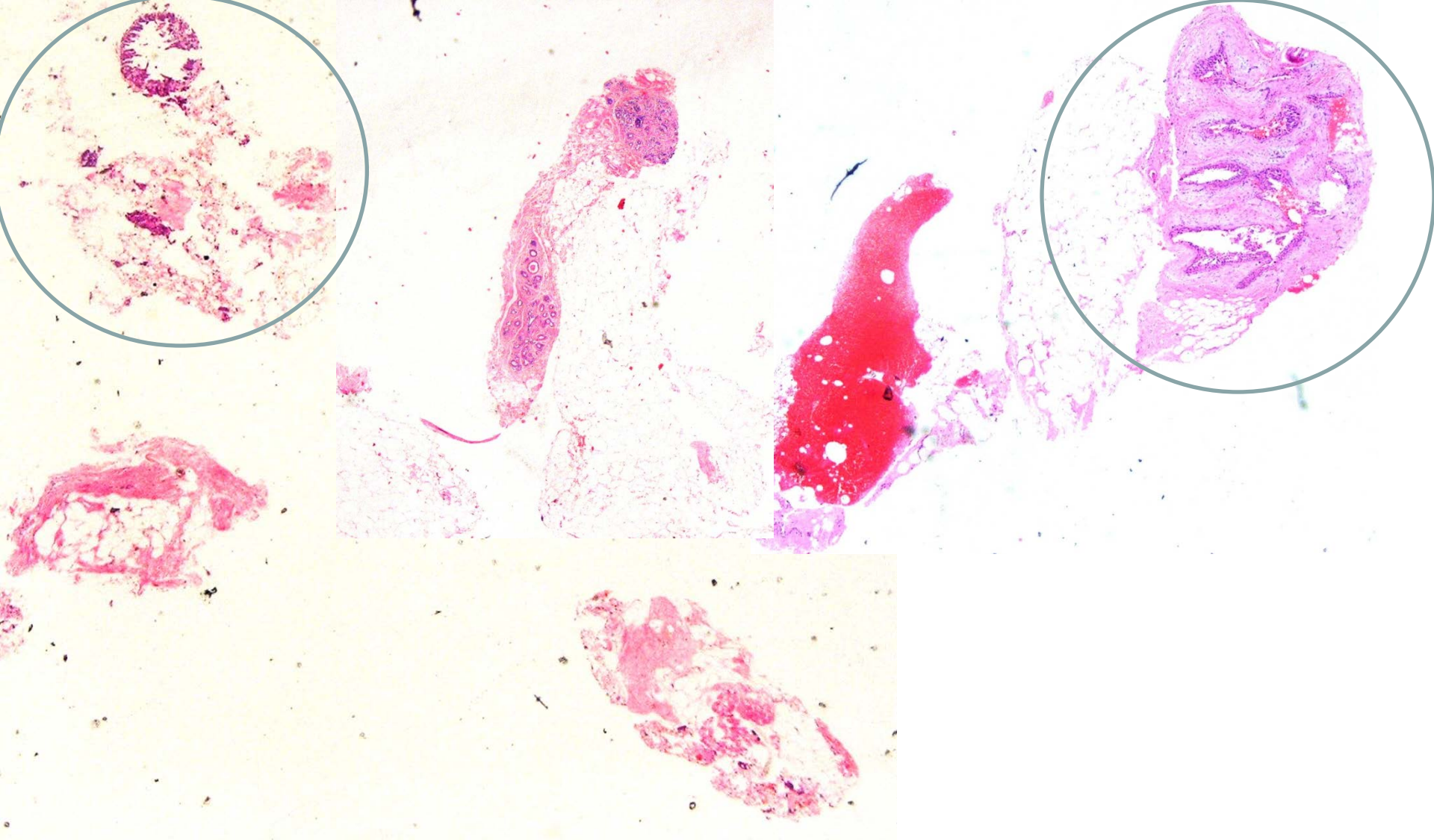

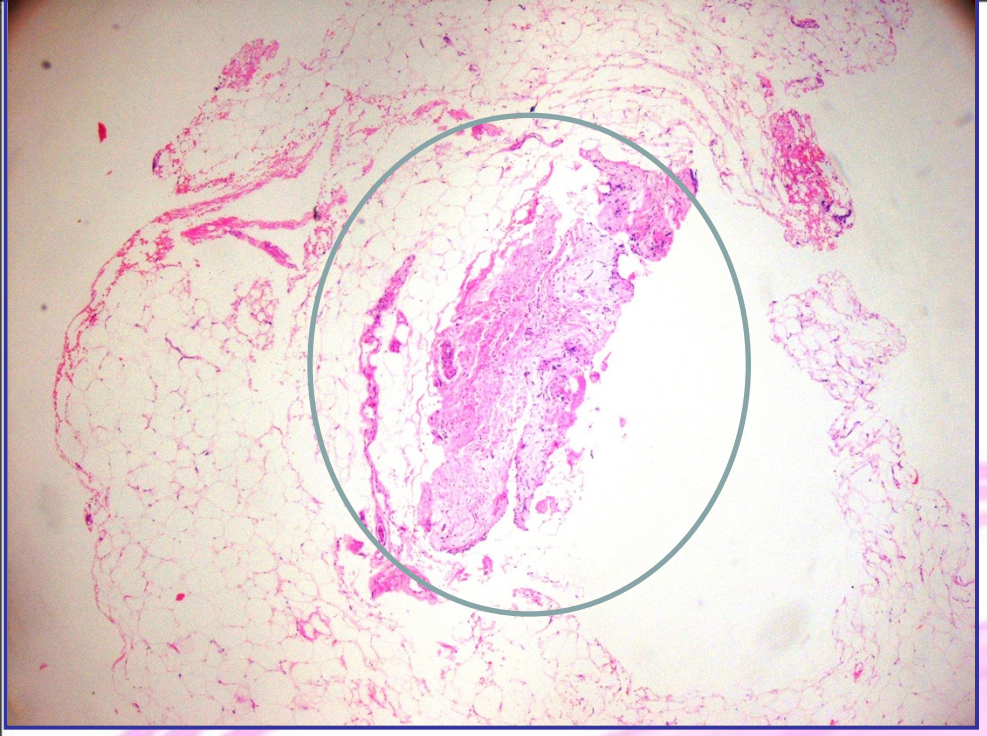

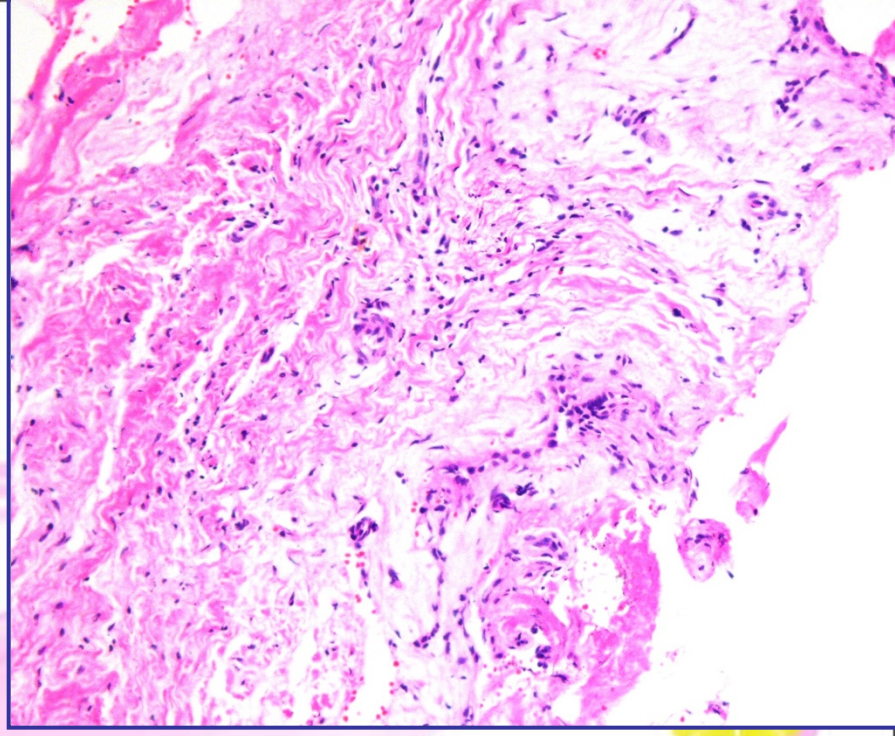

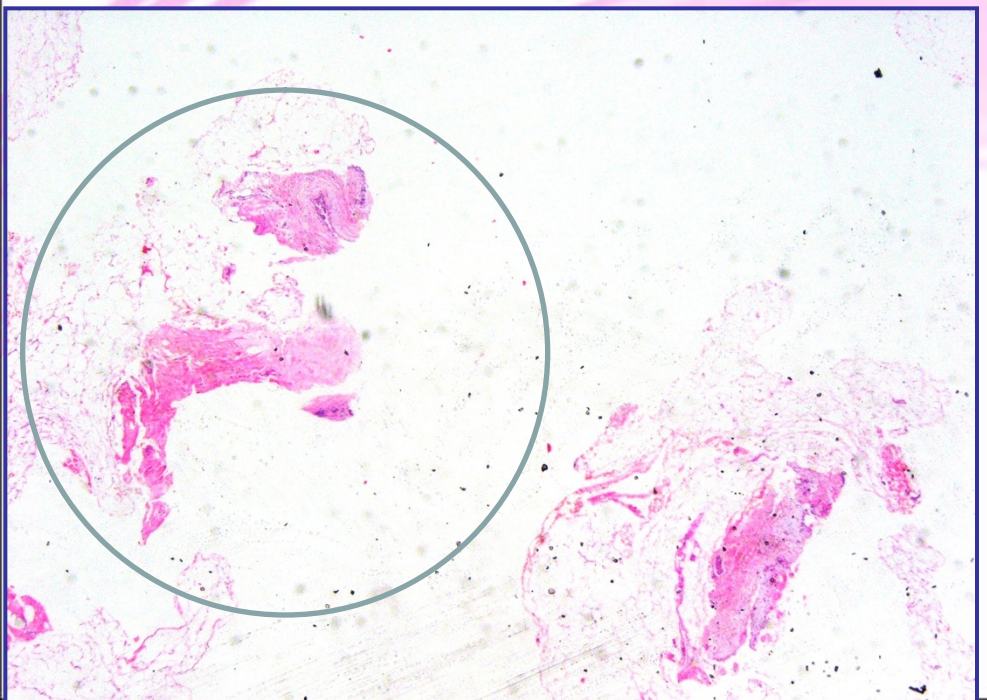

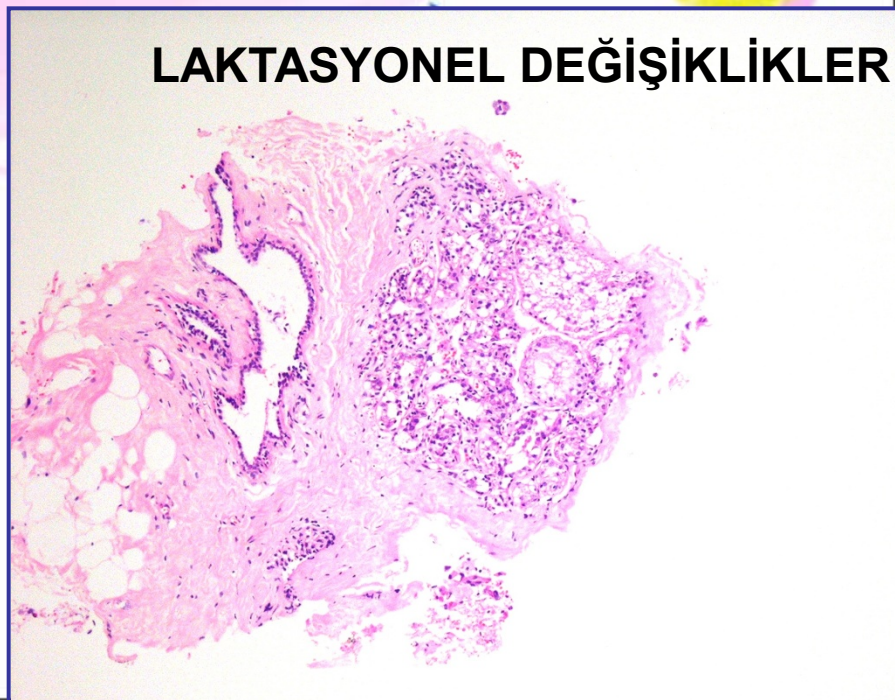

LAKTASYONEL DEĞİŞİKLİKLER

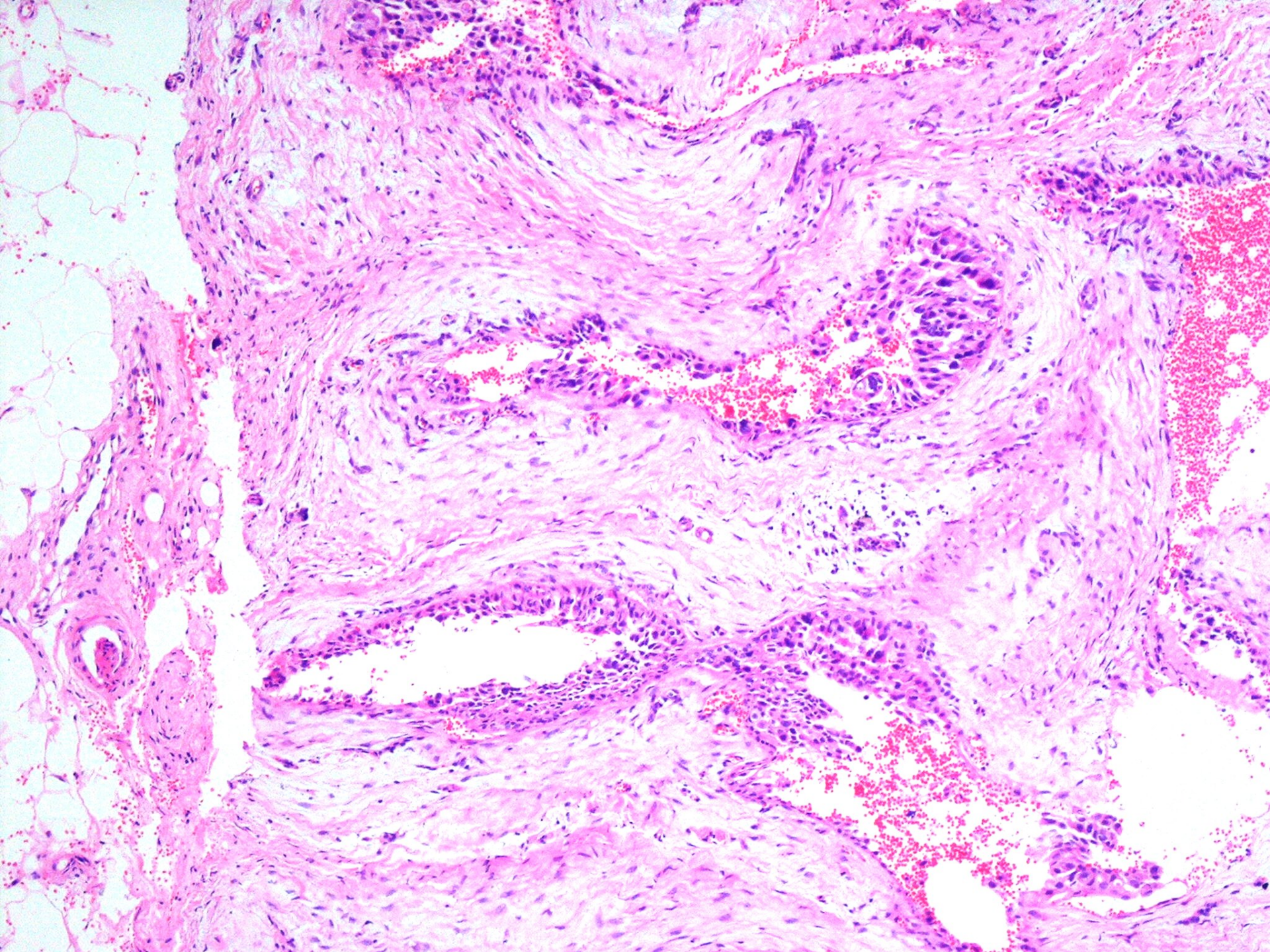

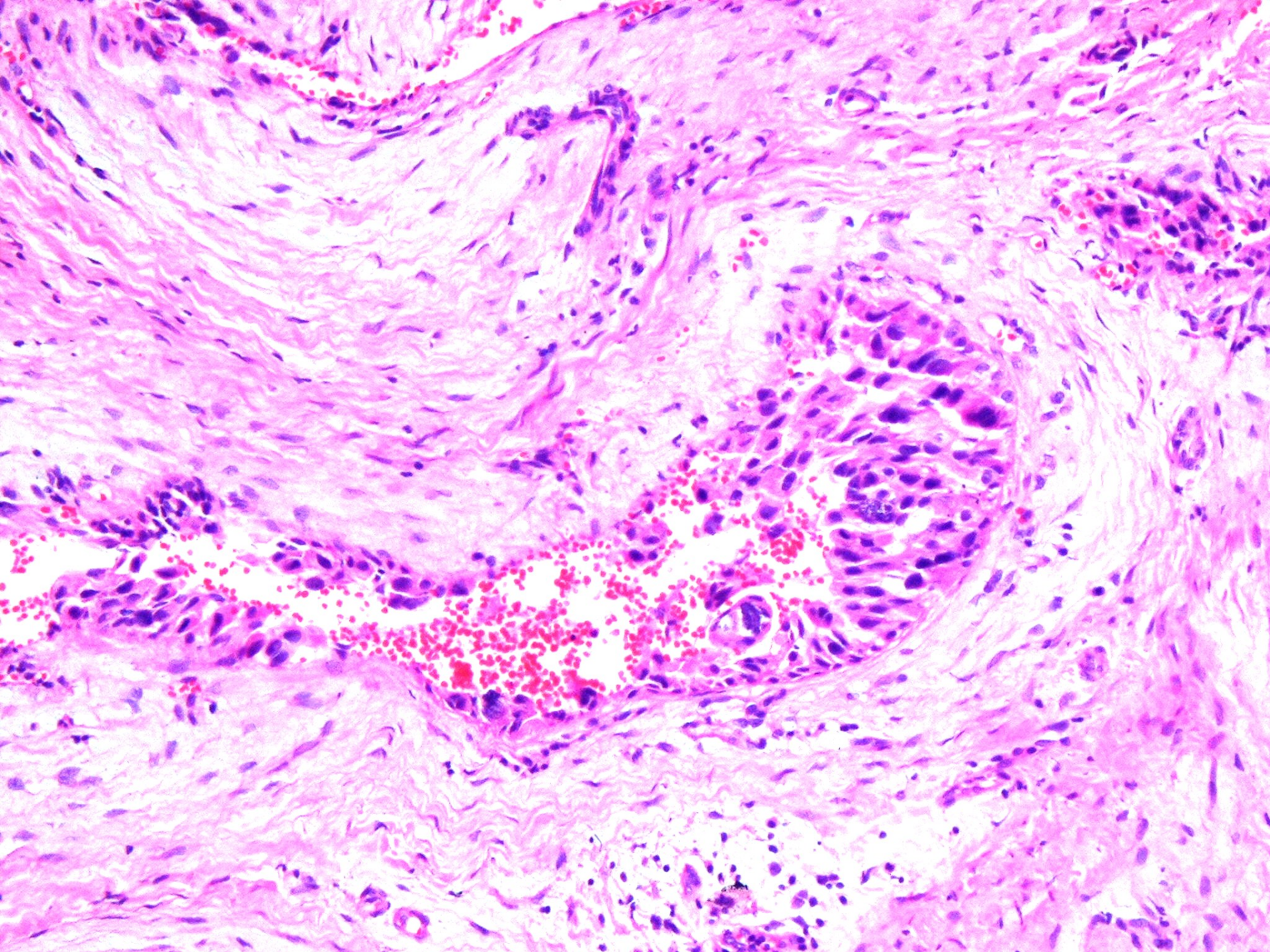

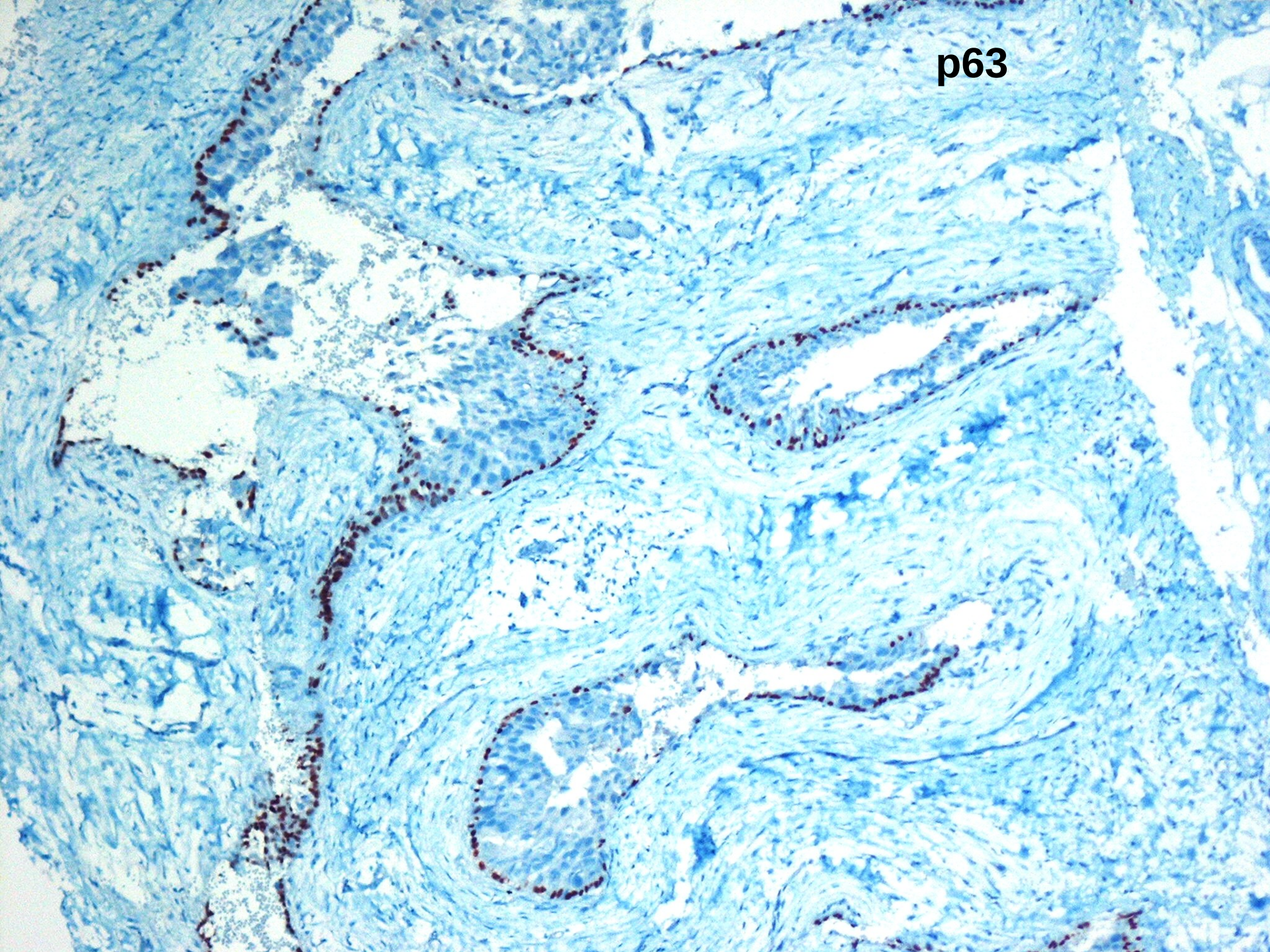
p63

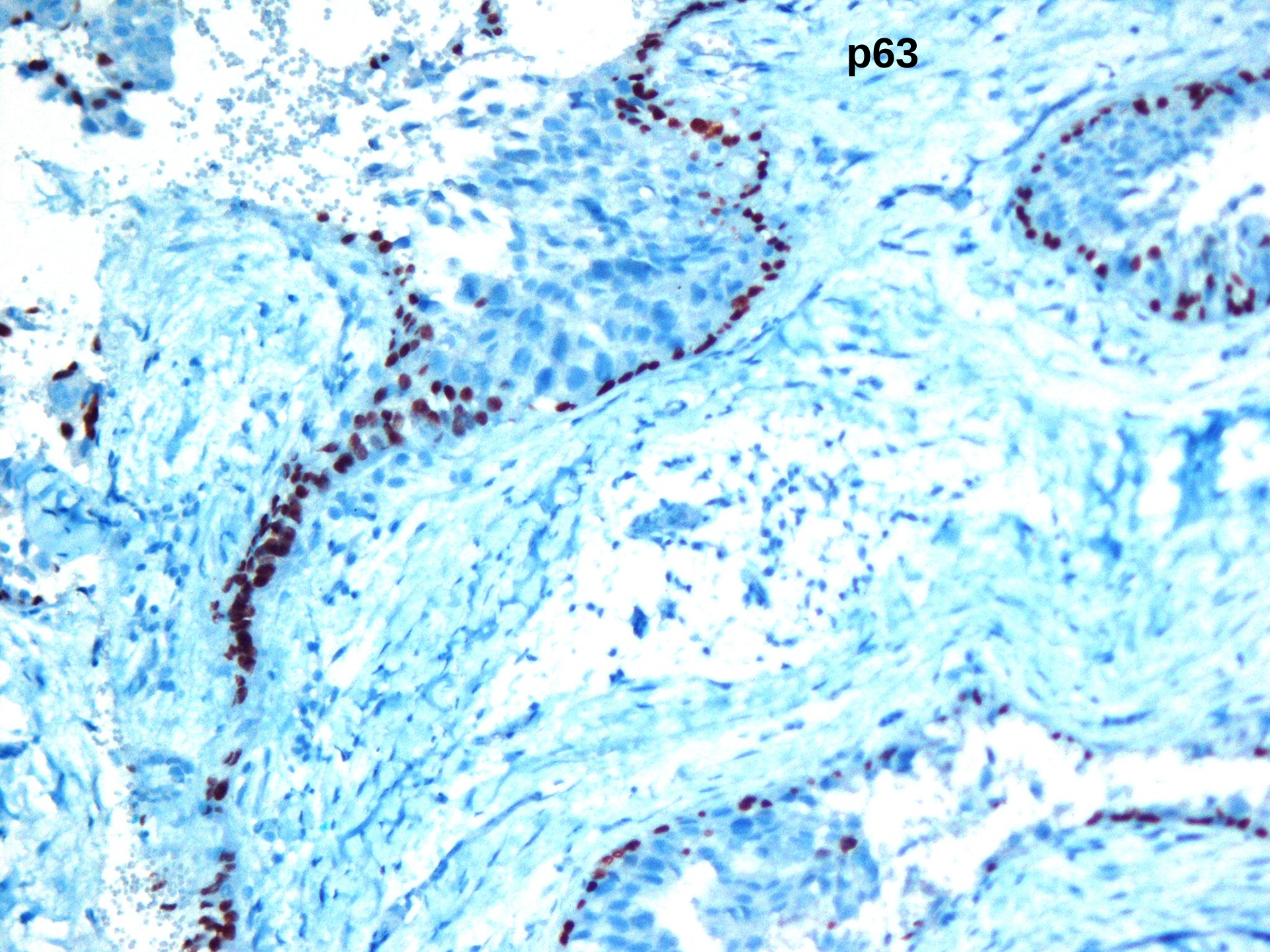
p63

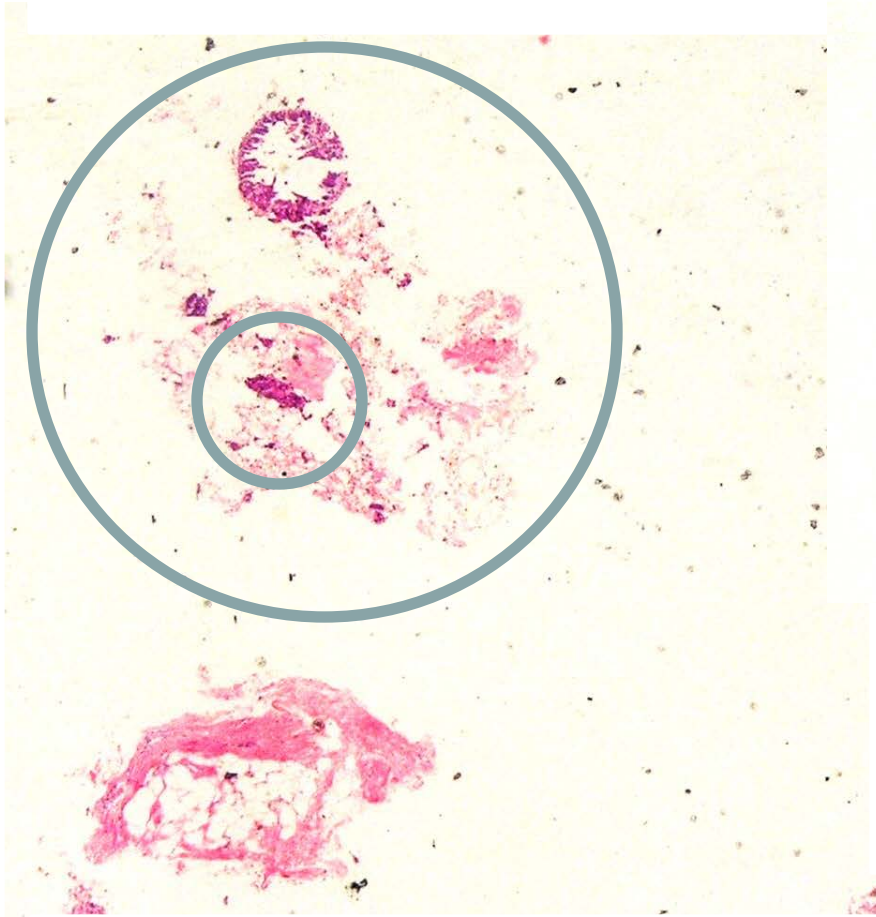

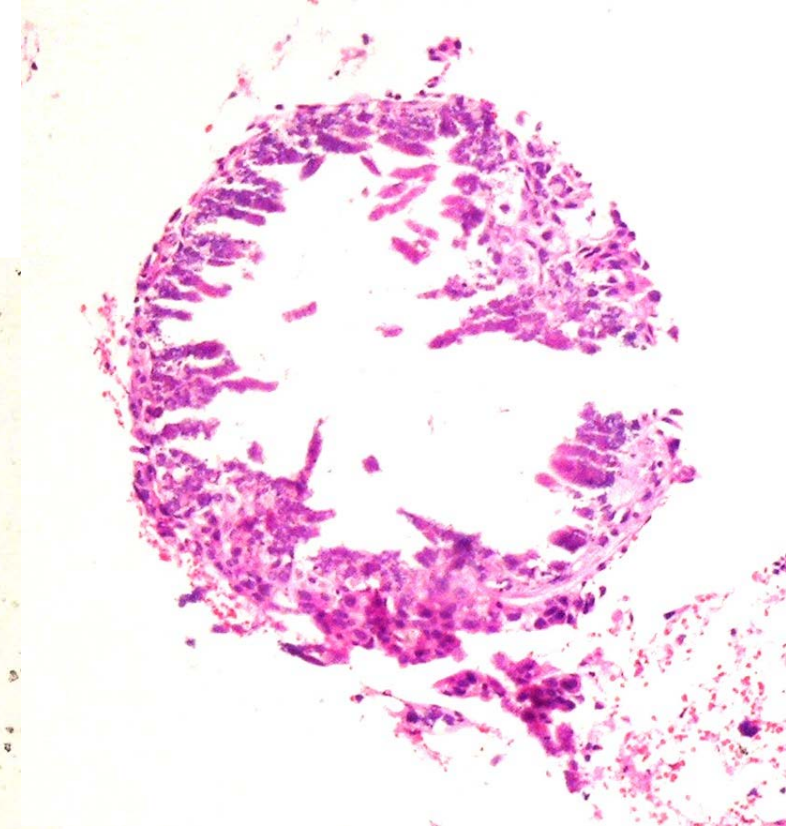

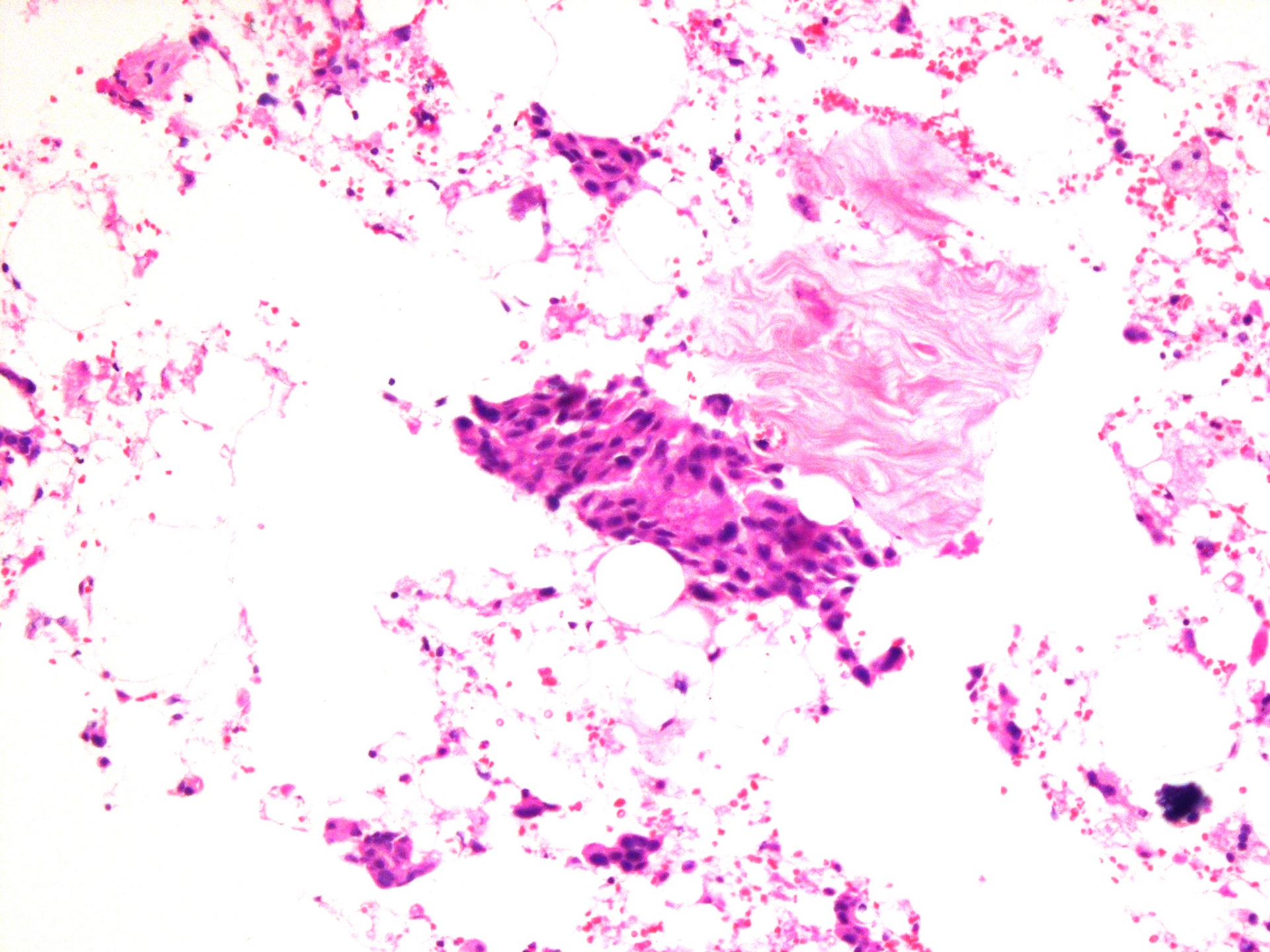

- DUKTAL KARSİNOMA İN-SİTU
- GRADE 3/3
- MİKROKALSİFİKASYON KÜMELERİ.
- MİKROİNVAZYON YÖNÜNDEN KUŞKULU GLAND BENZERİ YAPILAR.

www.fppt.info

LUMPEKTOMİ

- 6.5x5x0.4 cm tel ile işaretli meme biyopsisi.
- Cerrahi sınırları ip ile işaretli.
- Hematom alanları ve kirli beyaz renkli alanlar içermekte.

- **İnferolateral kenardan reeksizyon**:

  6x5x3 cm, kirli beyaz renkli alanlar içeren meme dokusu

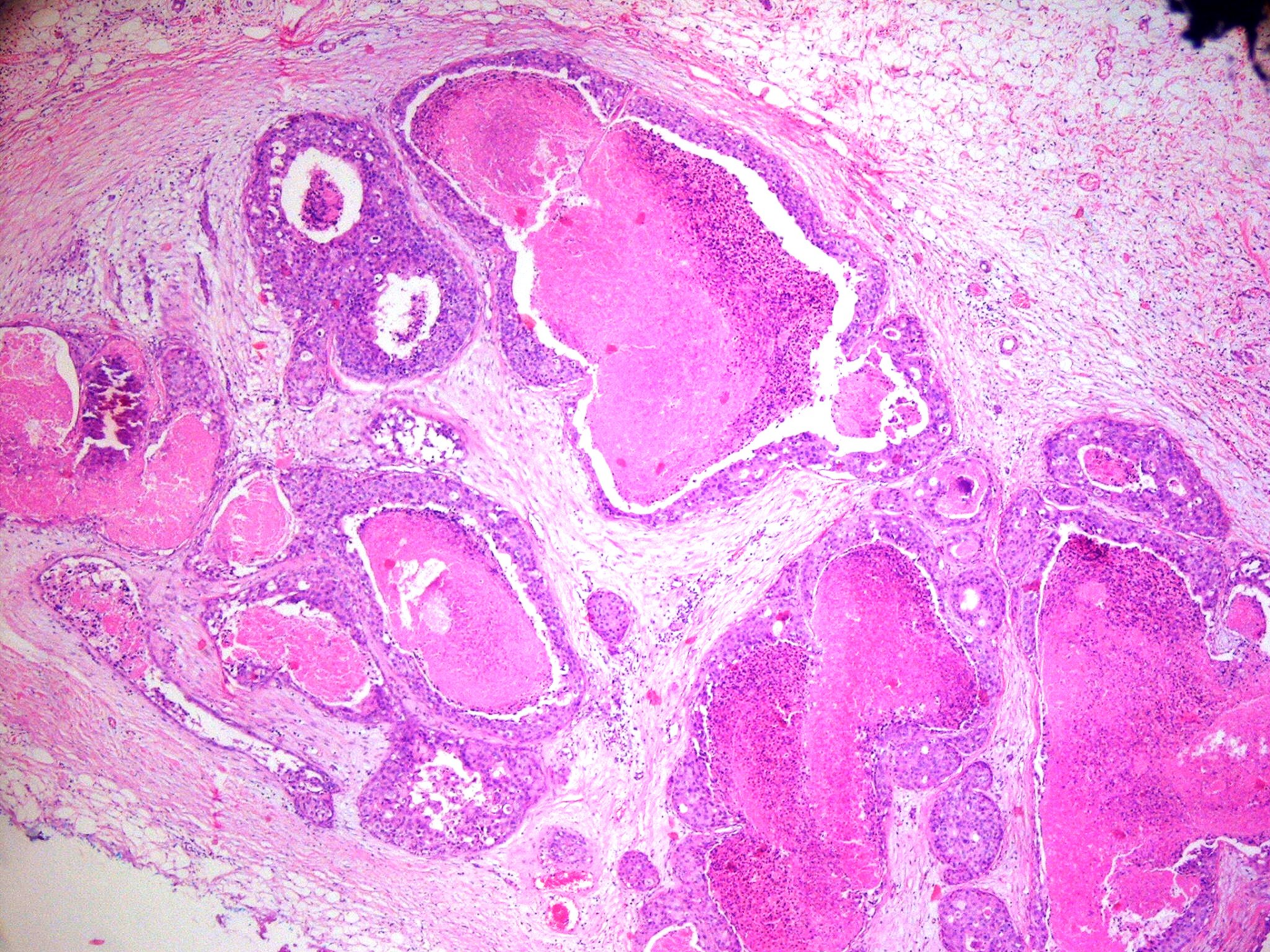

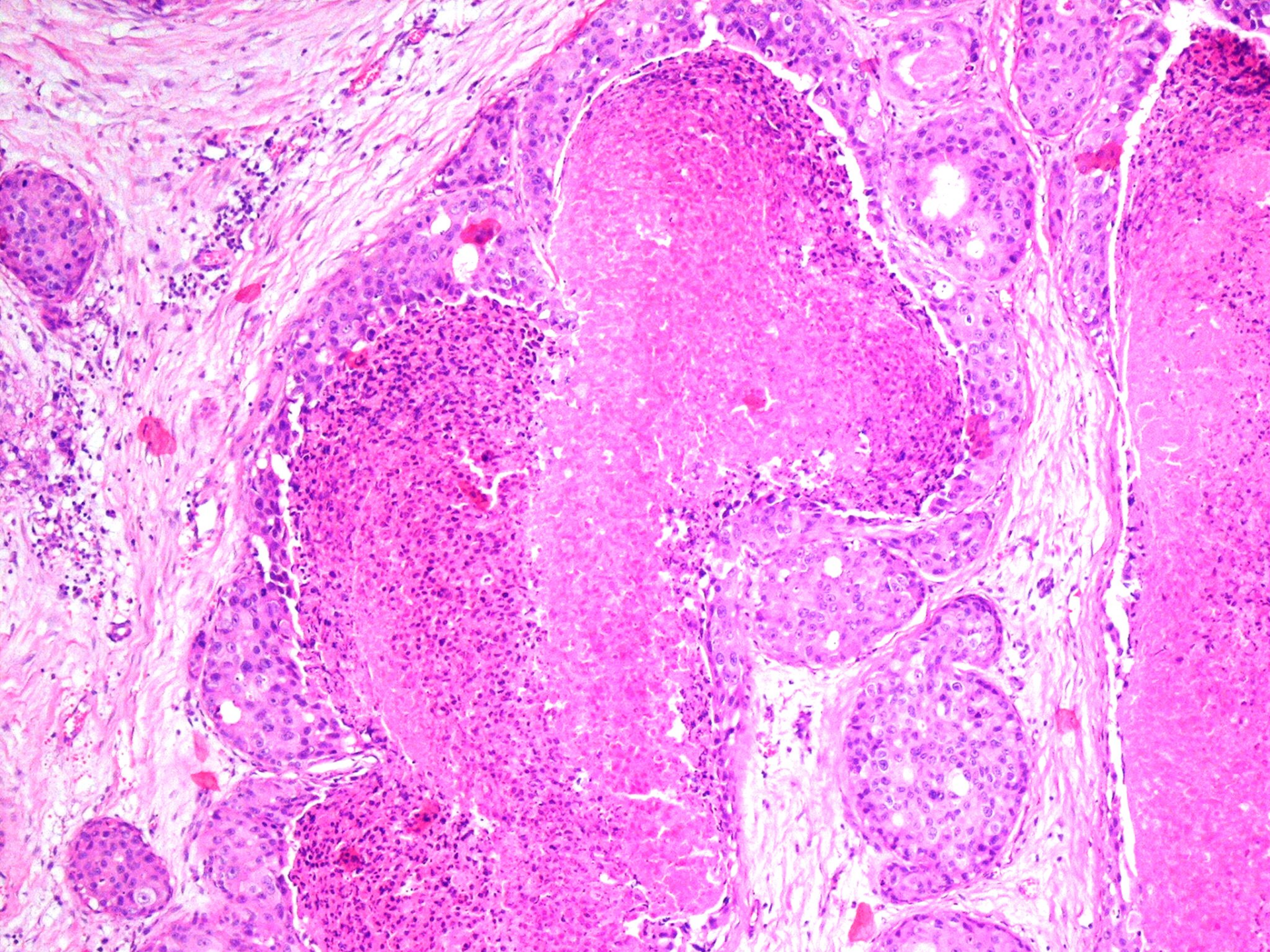

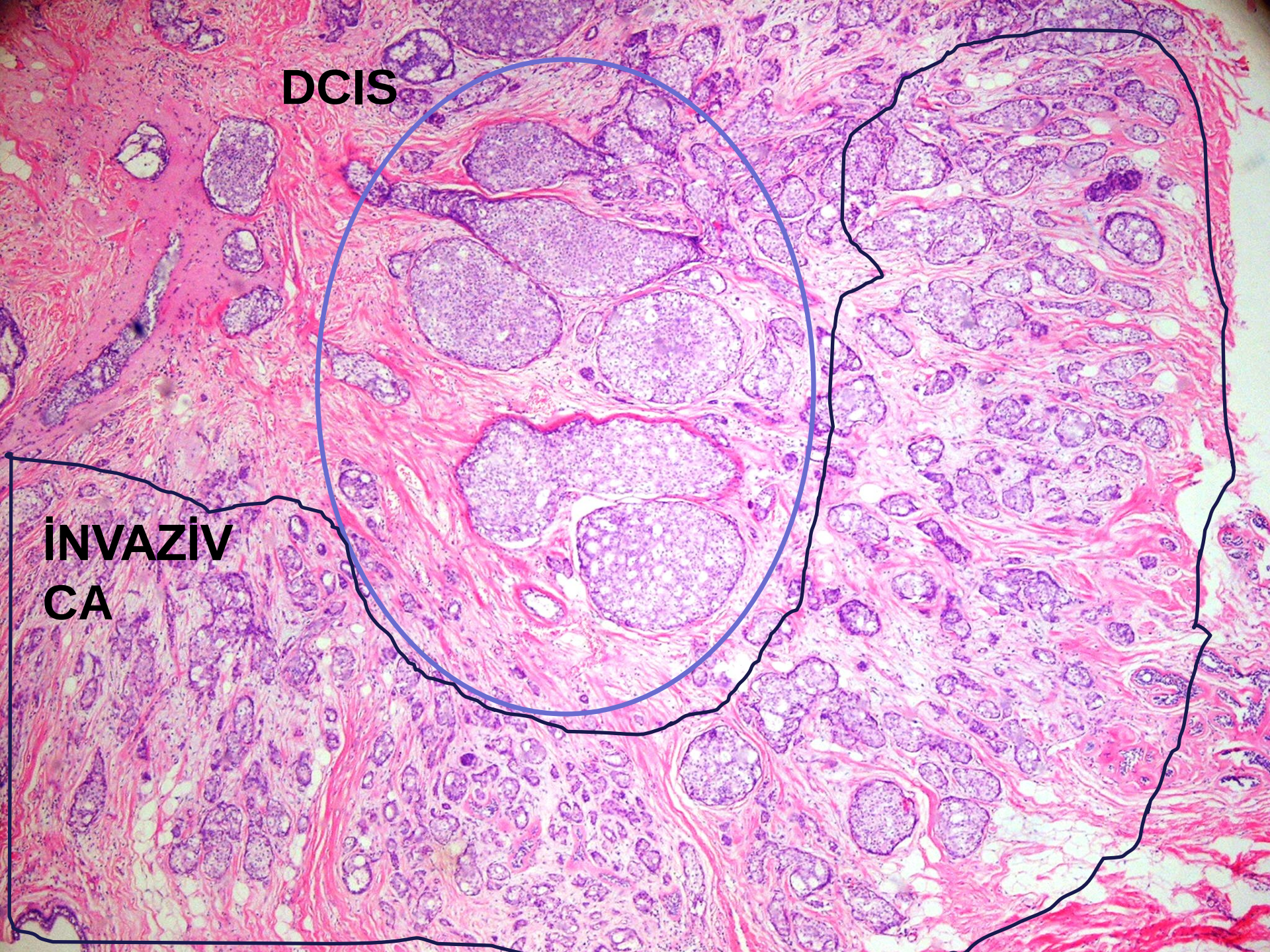
DCIS
İNVAZİV
CA

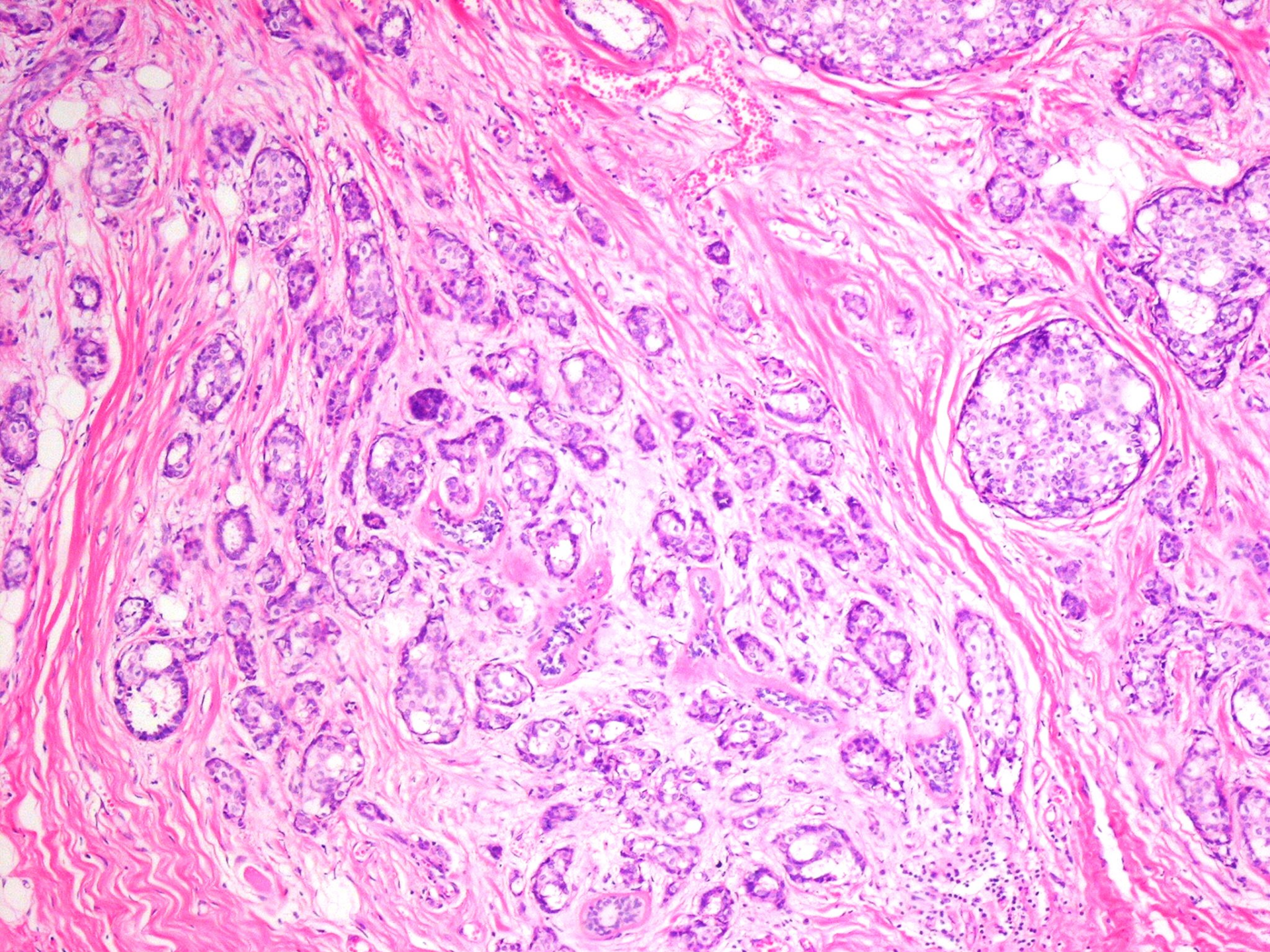

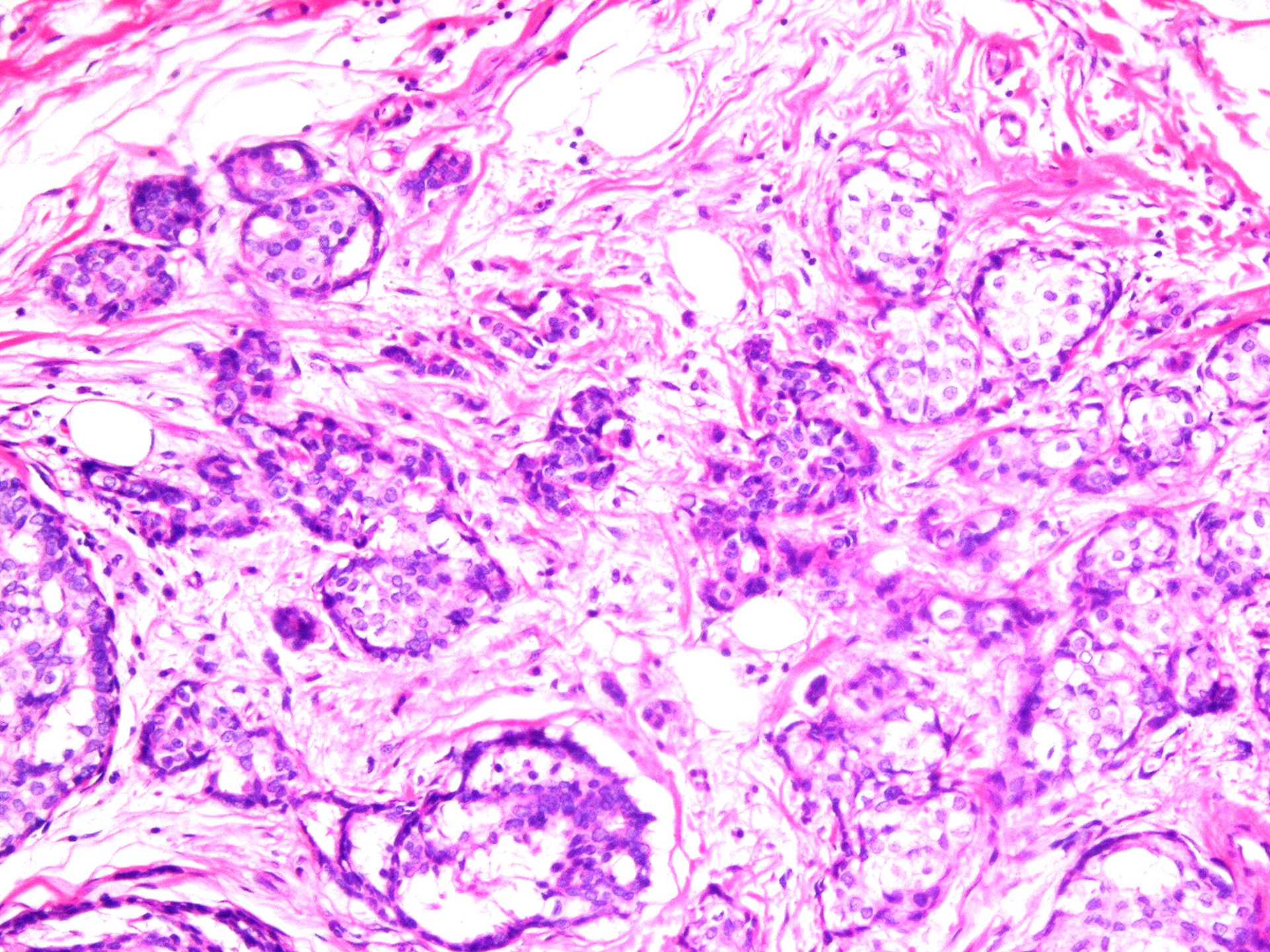

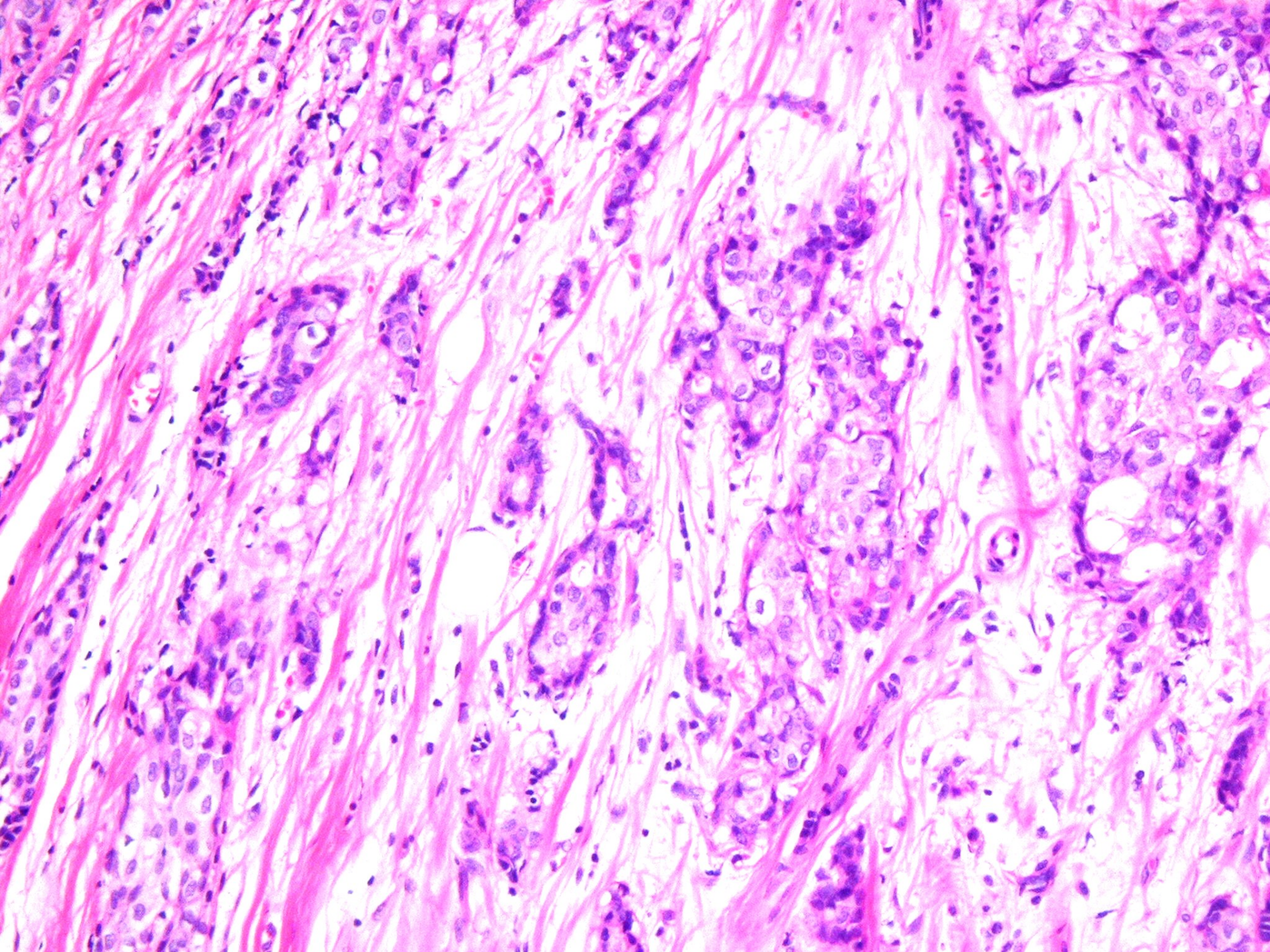

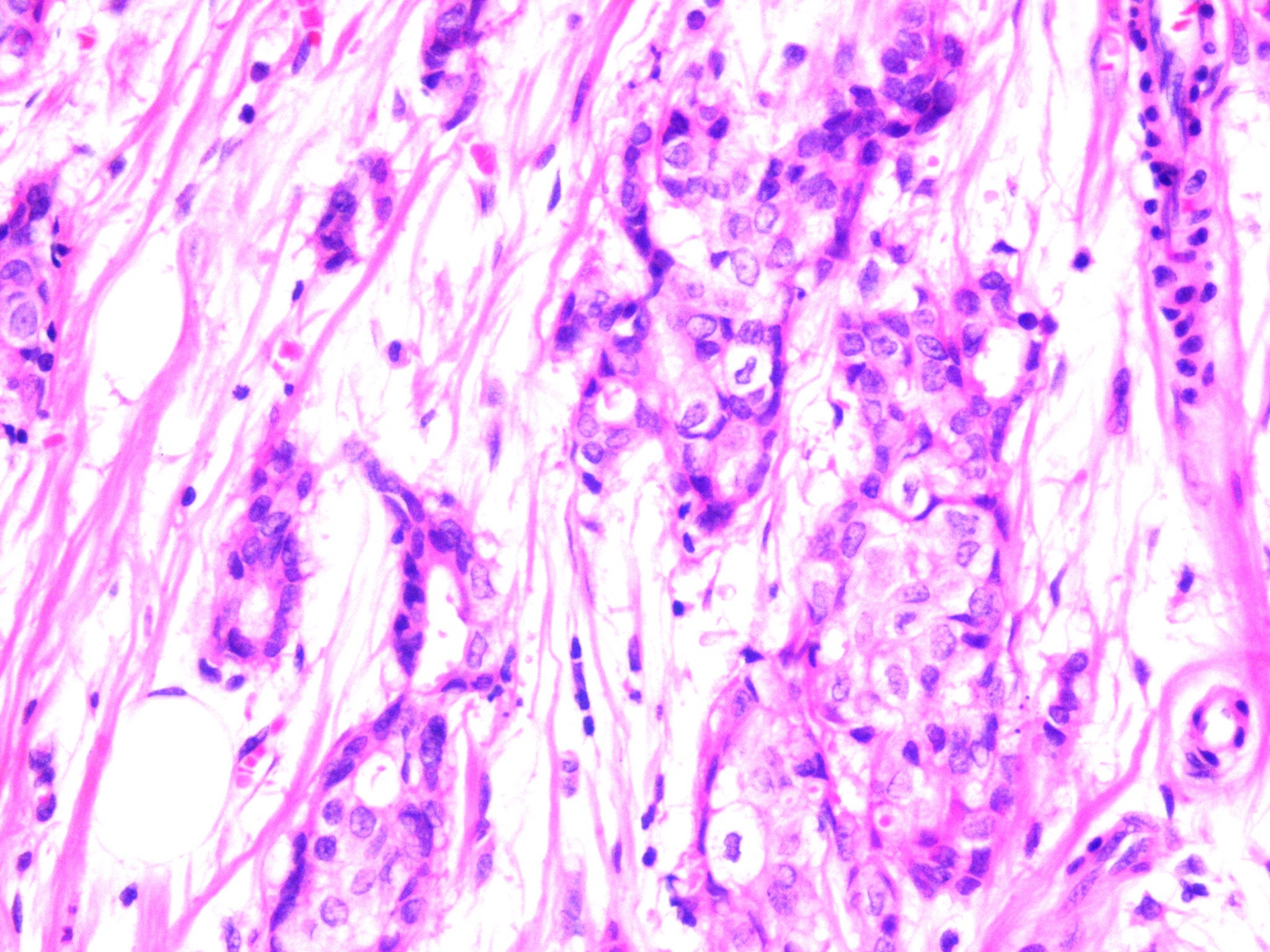

CALPONİN İLE MYOEPİTELYAL HÜCRE KAYBI

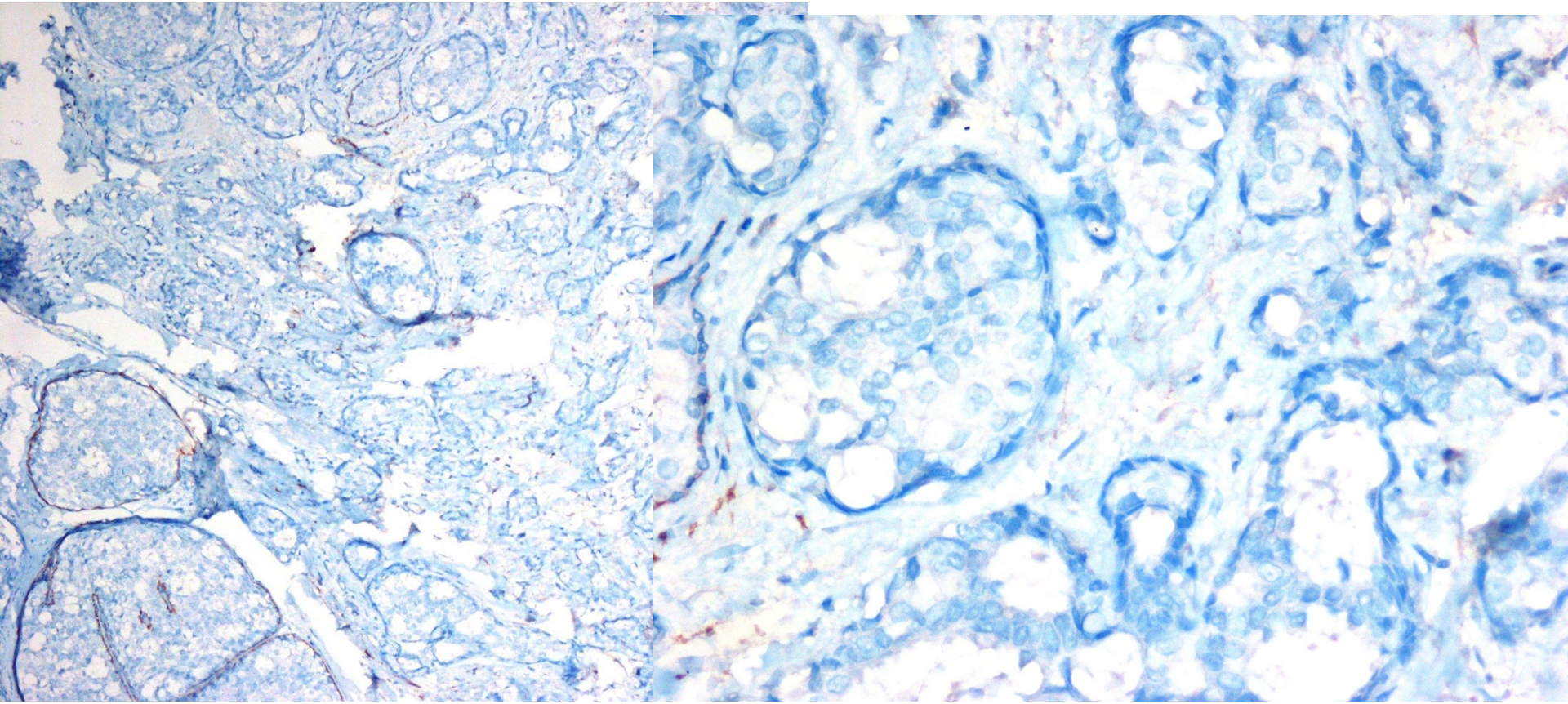

CERRAHİ SINIR POZİTİFLİĞİ

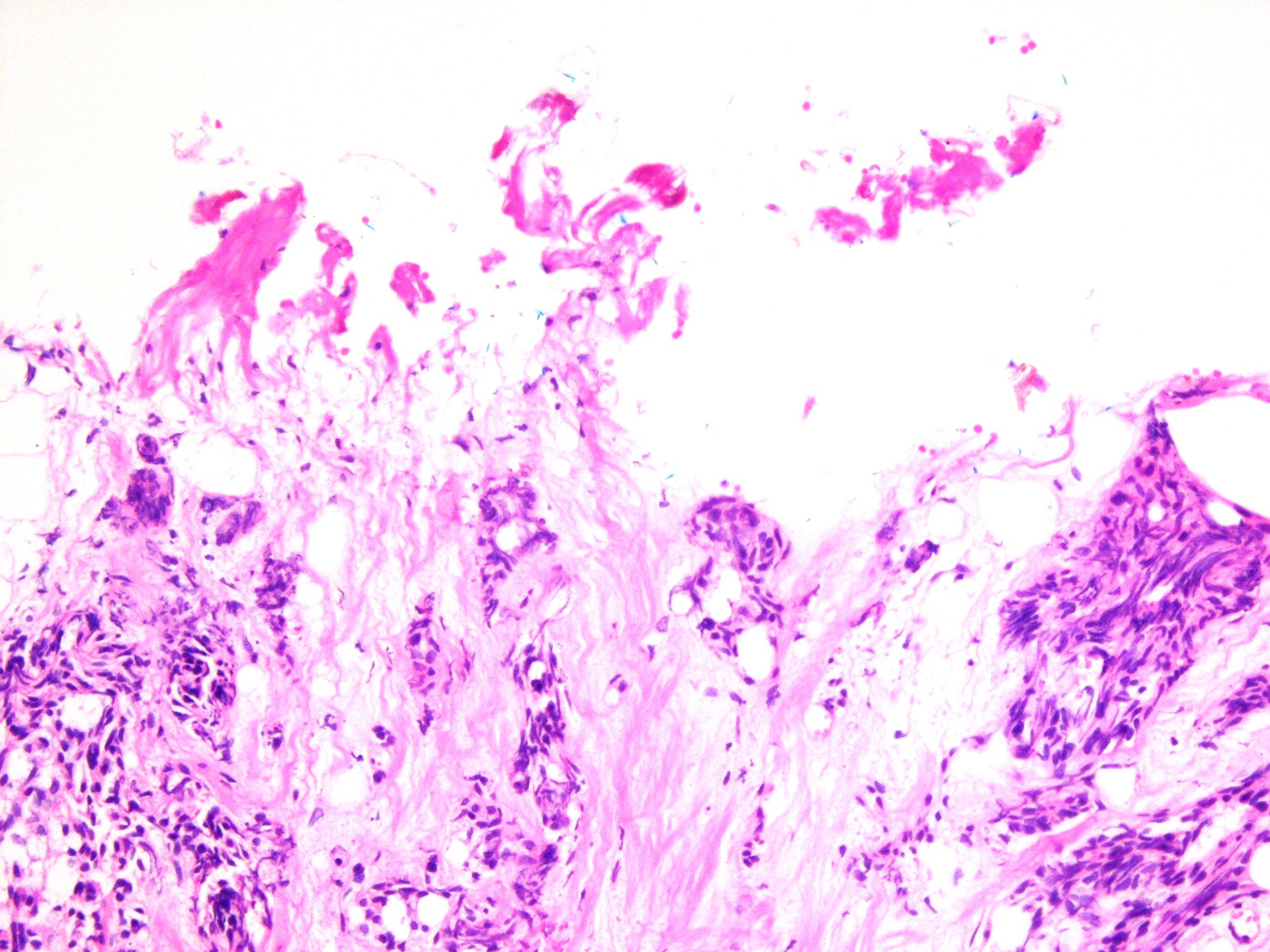

CERRAHİ SINIR POZİTİFLİĞİ

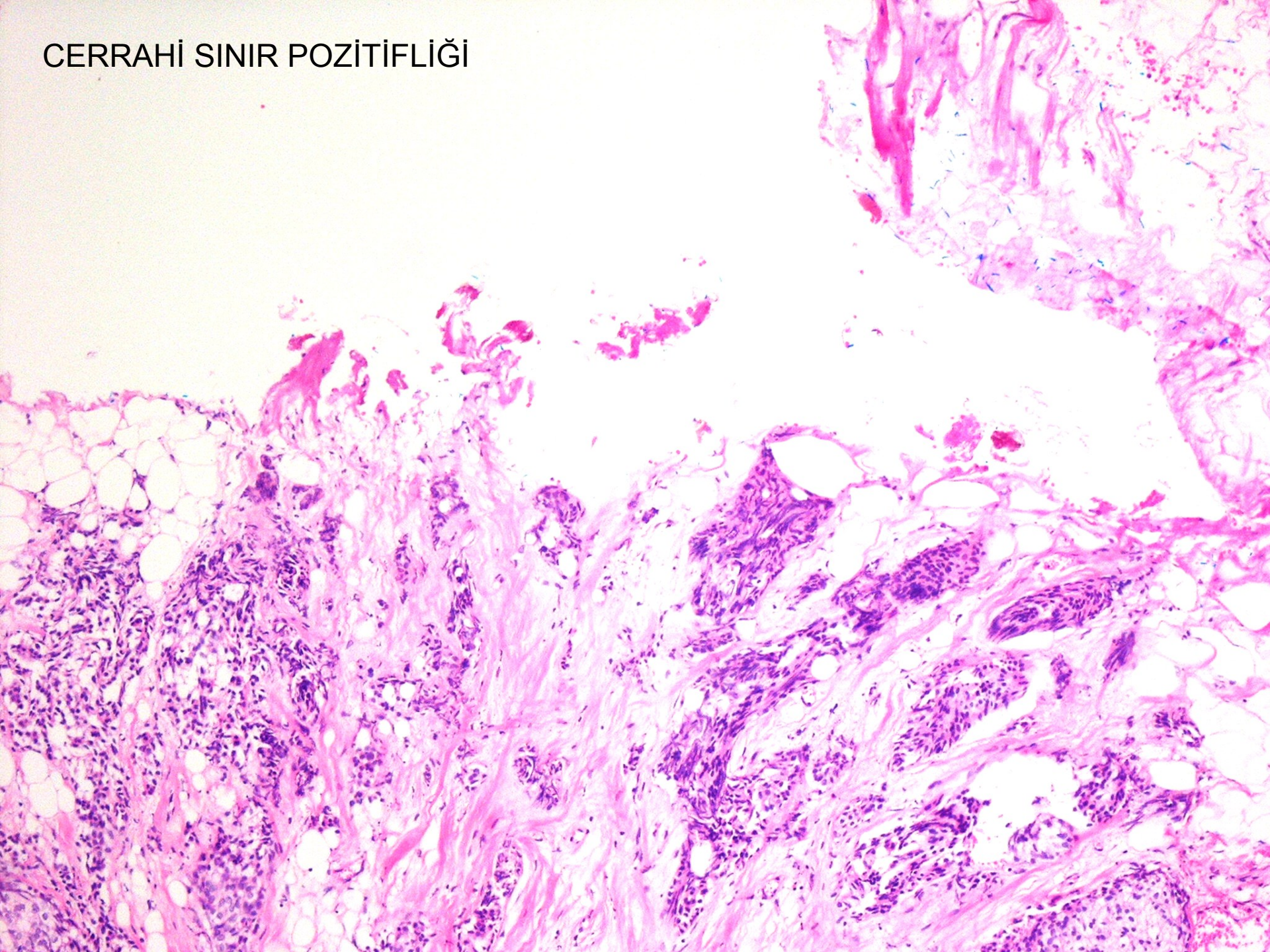

ÖSTROJEN RESEPTÖR

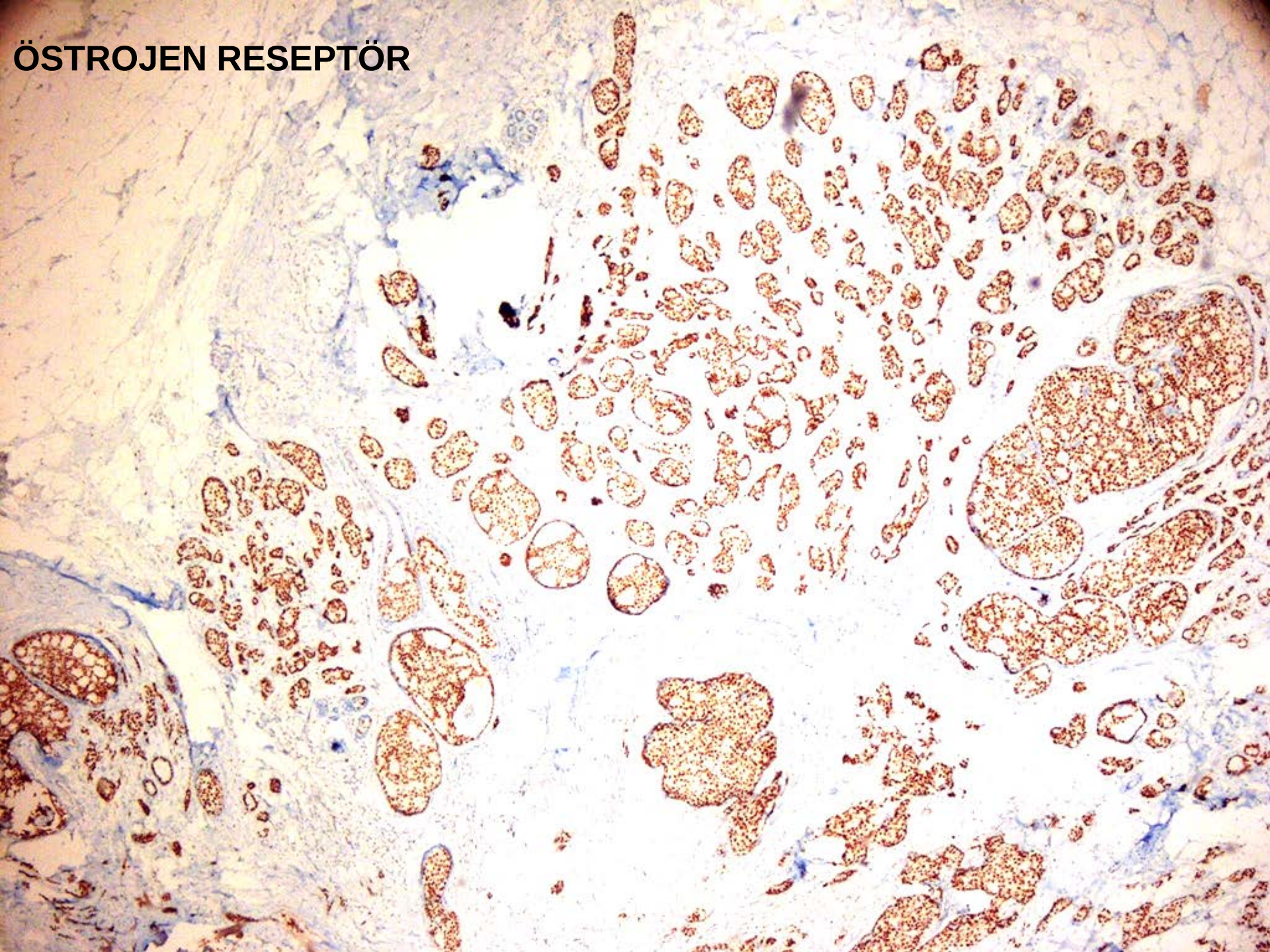

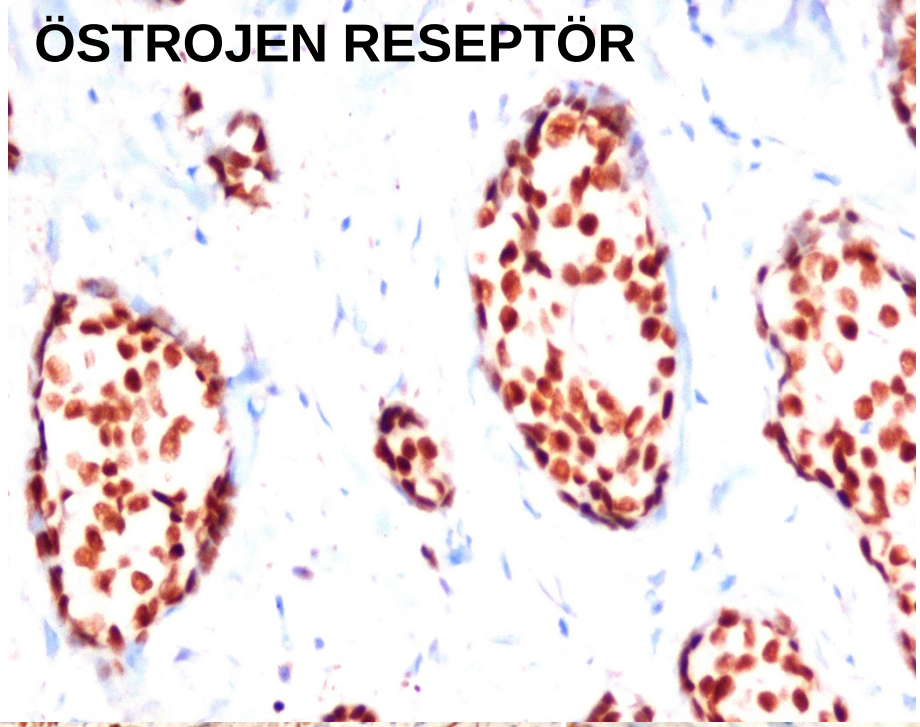
ÖSTROJEN RESEPTÖR

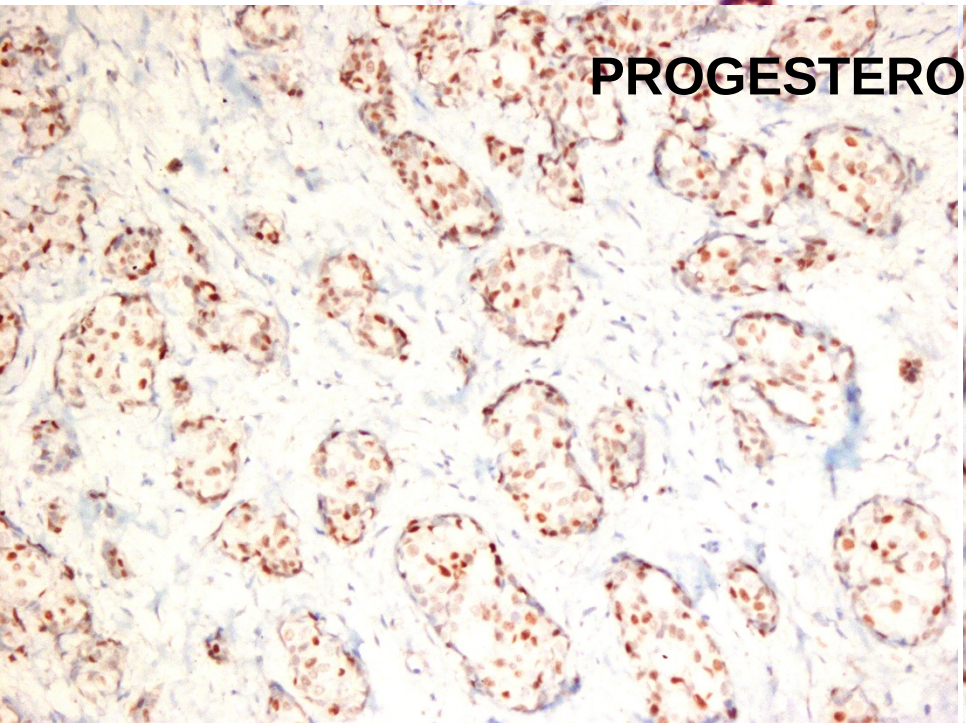
PROGESTERON RESEPTÖR

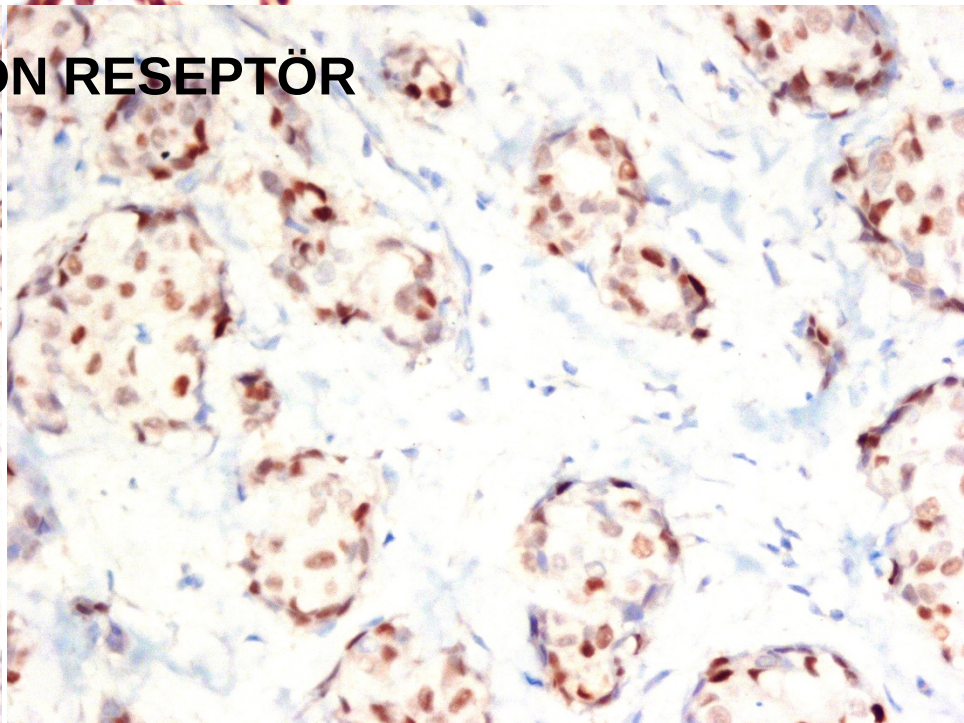

C-ERB-B2: 1(+)

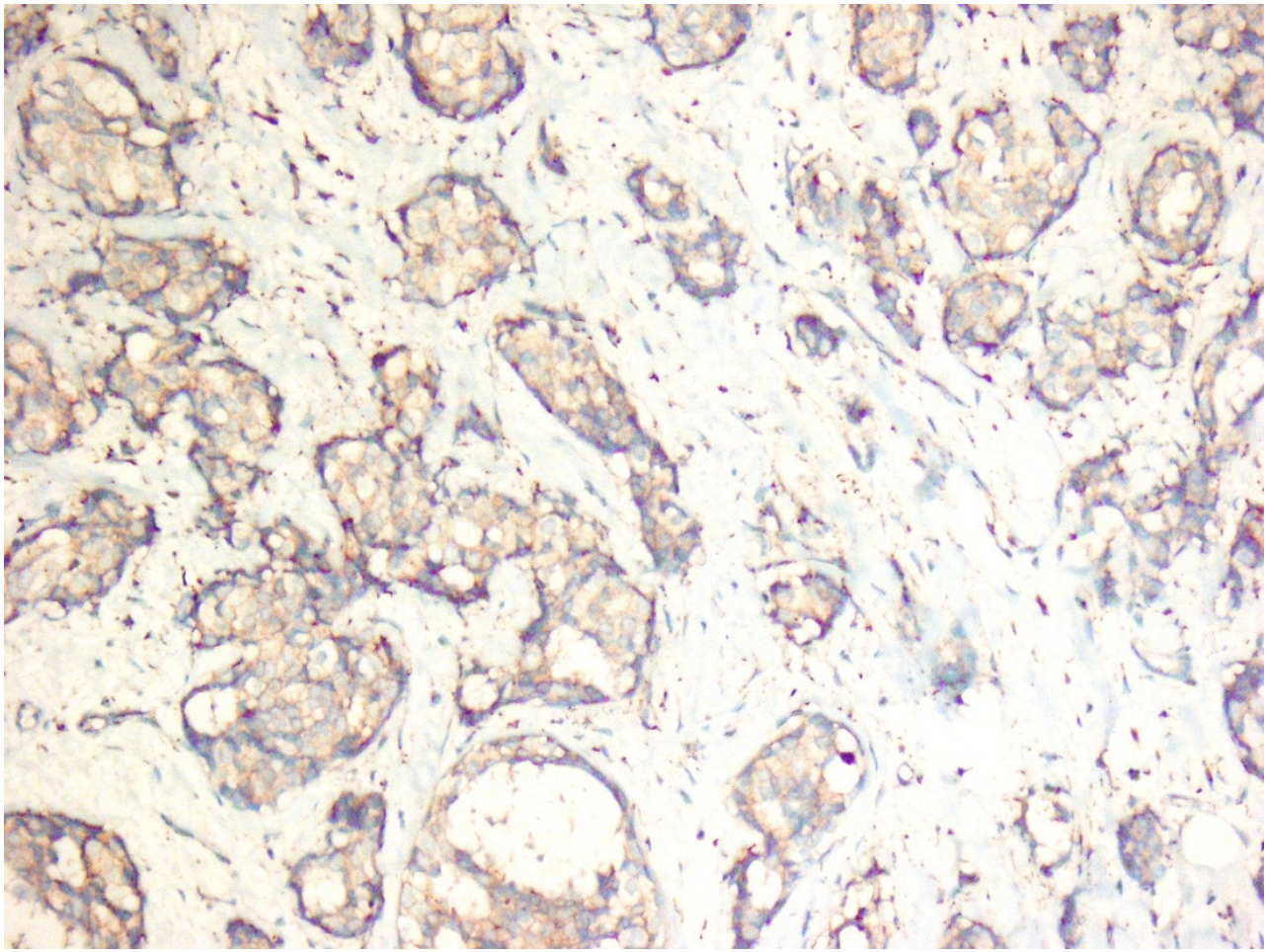

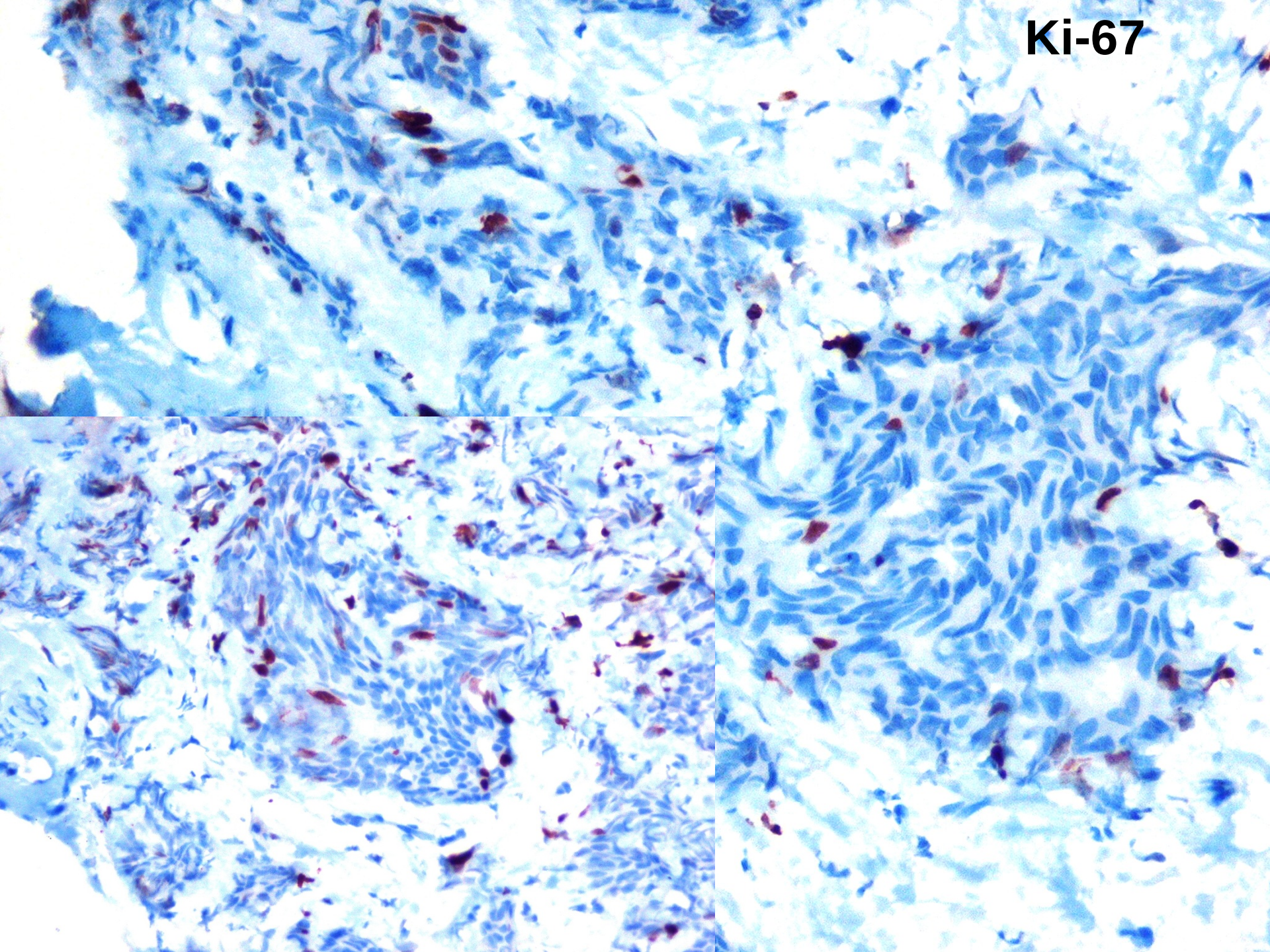
Ki-67

- İNVAZİV DUKTAL KARSİNOM
- GRADE 2/3
- Tümör çapı: 0.5 cm
- İnferianterior cerrahi sınırda devamlı
- İnvaziv alanlarda p63 ve Calponin kaybı
- Östrojen %95
- Progesteron %60
- C-erbB2: 1(+)
- Ki-67: < %5

- Çevre meme parankiminde yaygın intraduktal karsinom, yüksek dereceli
- Komedonekroz mevcut.

- İnferiolateral kenardan yapılan reeksizyonda tümör yok.

www.fppt.info

MODİFİYE RADİKAL MASTEKTOMİ

www.fppt.info

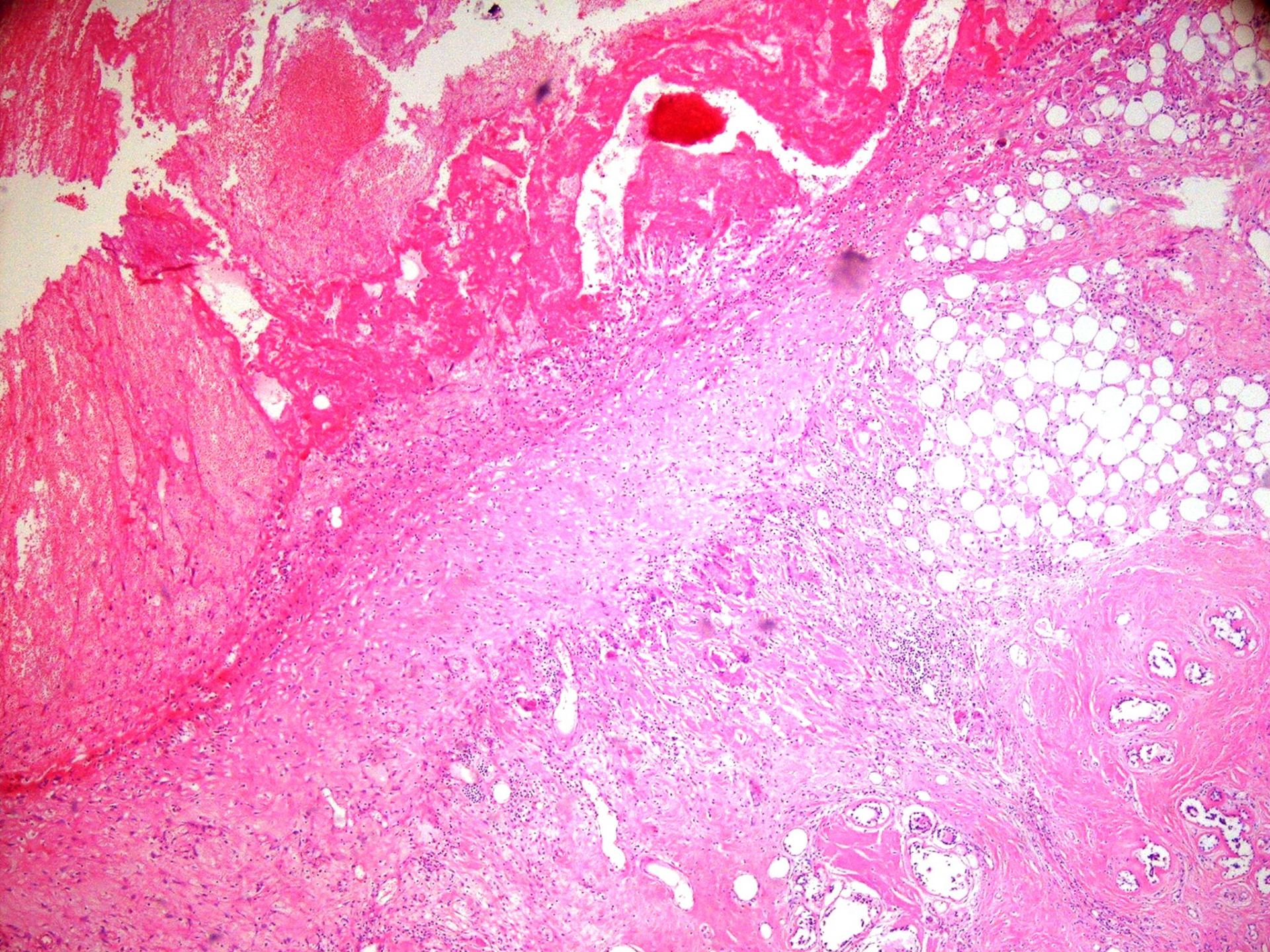

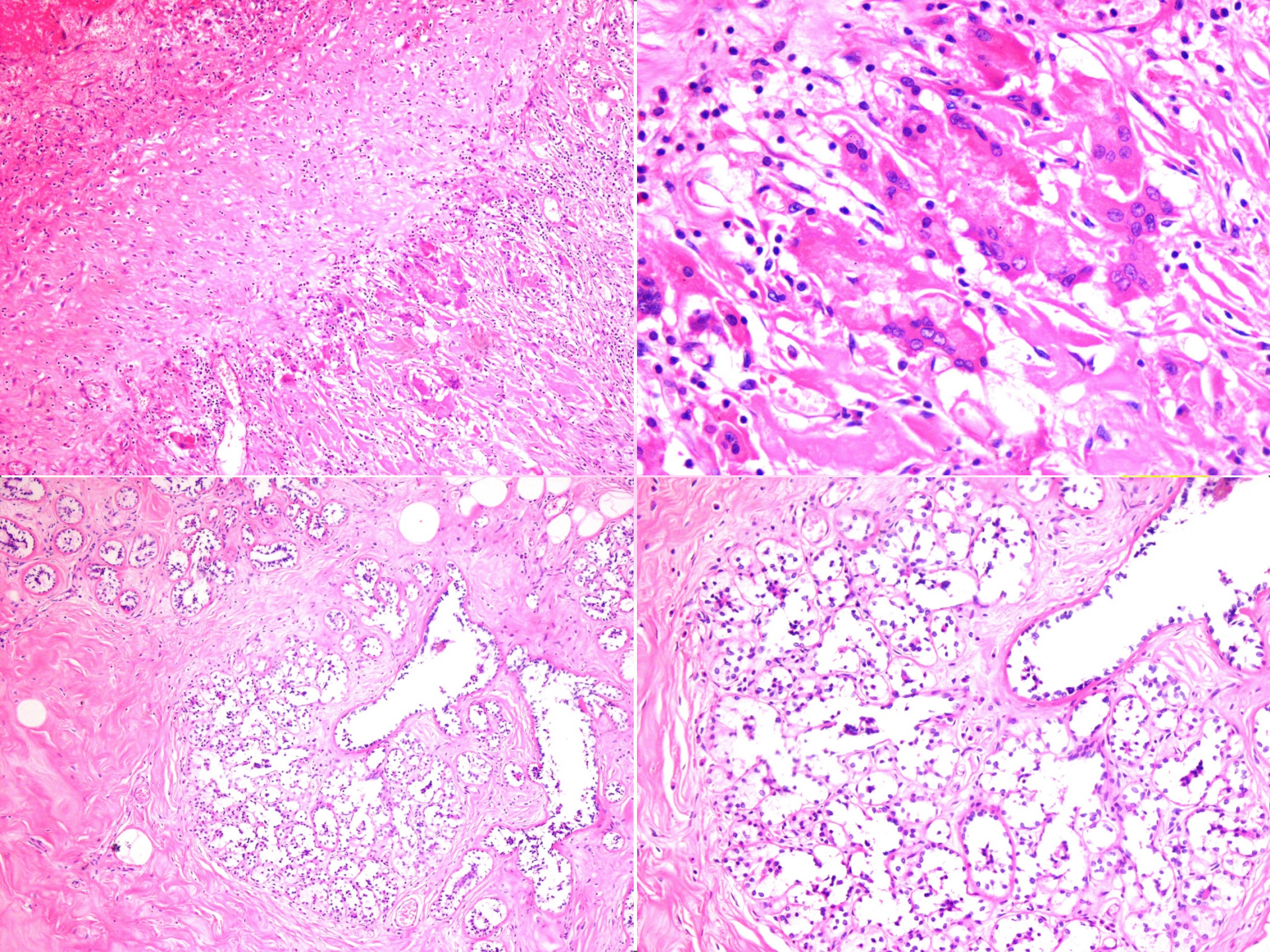

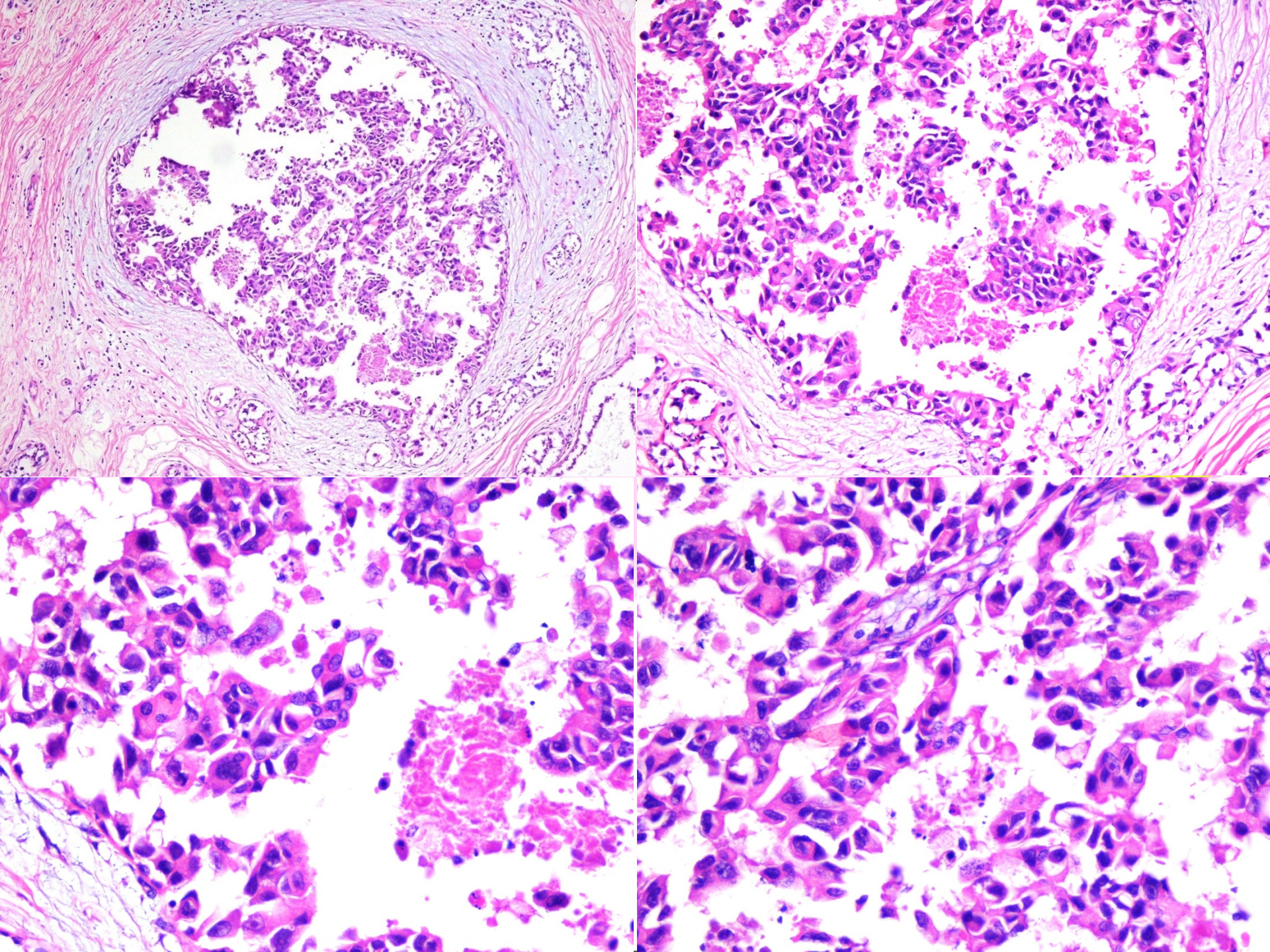

LOBULLERİN KANSERİZASYONU

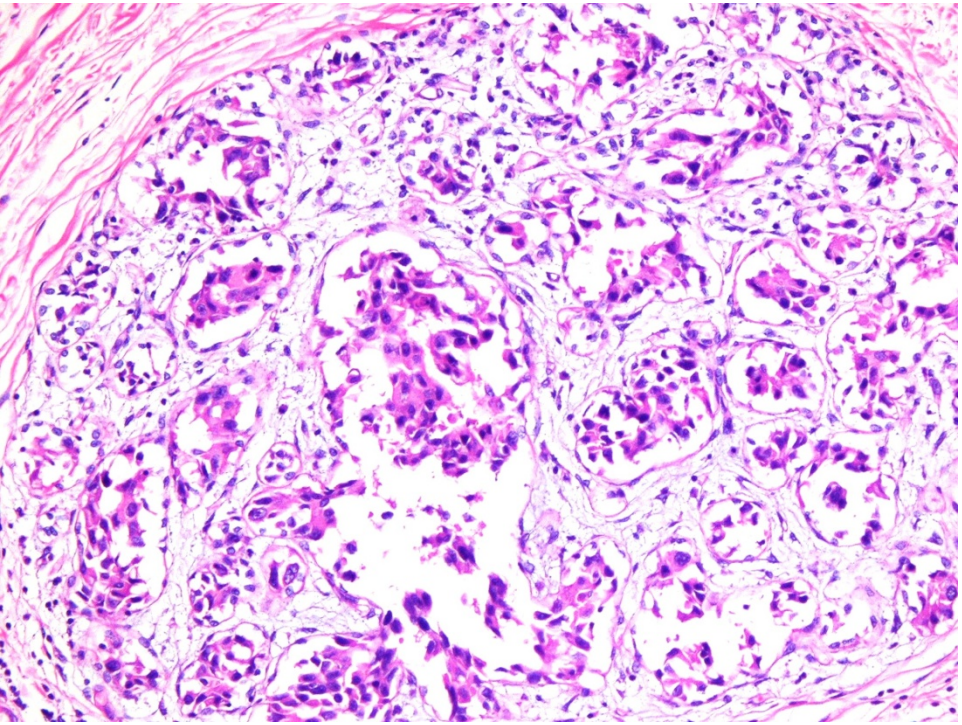

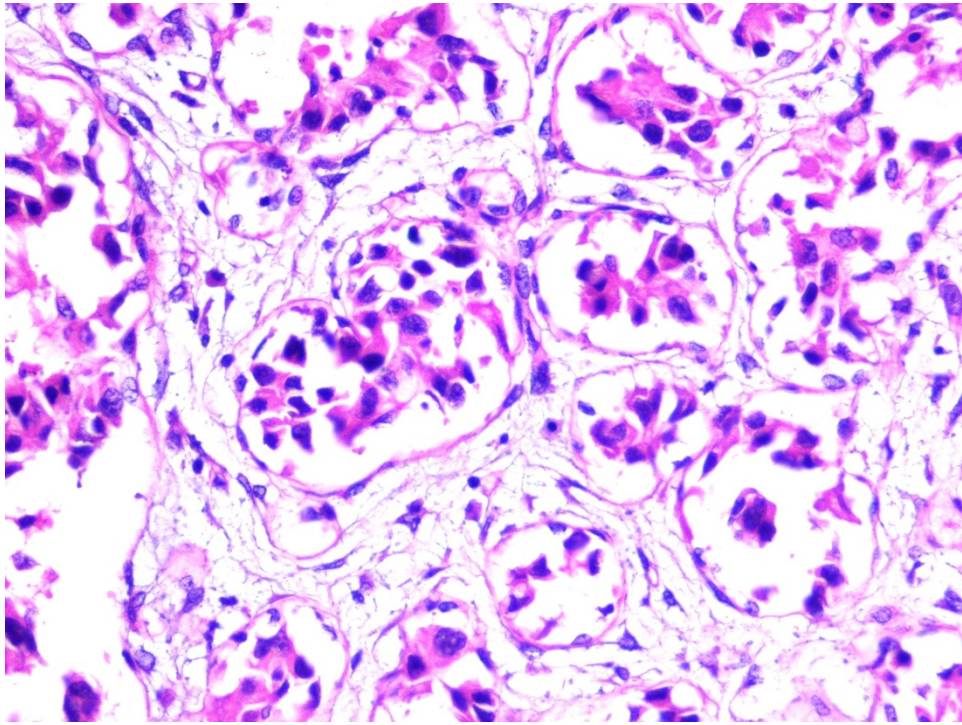

- Rezidü invaziv karsinom içermeyen meme parankimi
- Duktal Karsinoma İn-Situ, Grade 3, Komedonekroz izlenmiştir.
- Yabancı cisim tipi dev hücre reaksiyonu, iltihabi granülasyon dokusu ve laktasyonel değişiklikler gösteren meme lobulleri

- Meme başı, fasiya, deri dokusu doğal
- 17 adet reaktif lenf nodu, aksiller bölge
- 1 adet reaktif lenf nodu, intraparankimal

GEBELİK İLİŞKİLİ MEME KANSERİ

www.fppt.info

www.fppt.info

Gebelik ilişkili meme kanseri (GİMK);

- Gebelik sırasında,
- Doğumdan sonraki ilk 1 yıl içinde ya da
- Hastanın emzirdiği herhangi bir zamanda gelişen meme kanseridir.
- 3000-10000 gebelikte 1 görülür.
- Çocuk doğurma yaşı geciktiği için GİMK’de artış söz konusudur.

Breast Care 2013;8:203-207

- Serviks kanseri,
- Malign melanom,
- Lenfoma,
- Meme kanseri gebelikte en sık görülen kanserler.

Breast Care 2013;8:203-207

GİMK ve Premenopozal Meme Ca

- İnvaziv duktal karsinom en sık
- İnvaziv lobuler, Musinöz ca, DKIS, lobullerin kanserizasyonu
- Daha ileri evre
- Lenf nodu metastazı daha sık
- Grade II-III
- Çoğunluğu ER (-), PR (–), c-erbB2 (+)

- Meme kanserinin prognozunda gebeliğin rolü nedir?

- Birçok çalışmada anlamlı ilişki bulunamamıştır.

Clin Oncol (R Coll Radiol) 1999;8:367–370.
Cancer 2009;115:1174–1184.
Am J Obstet Gynecol 1992;166:781–787.
Cancer 2003;98:1131–1140.
Acta Oncol 2008;47:545–549.
J Surg Oncol 2010; 101:534–542.

- Başka çalışmalarda; tanının gecikmiş olmasına bağlı olumsuz etkilerden bahsedilmiştir.

Jpn J Cancer Res 1992;83:1143–1149.
J Exp Clin Cancer Res 2003;22:23–27.
J Clin Oncol 2010;28:1589.
Int JCancer 1996;67:751–755.
Acta Oncol 2012;51:653–661.

- Başka çalışmalarda ise gebeliğin meme kanserinde kötü prognostik etkisinin olduğu bildirilmiştir.

Obstet Gynecol 2008;112:71–78.
Int J Cancer 1997;72:720–727.
Sao Paulo Med J 2010;128:119–124.

Breast Care

Original Article · Originalarbeit

Breast Care 2013;8:203–207
DOI: 10.1159/000352093

Published online: June 28, 2013

Does Pregnancy-Associated Breast Cancer Imply a Worse Prognosis? A Matched Case-Case Study

Constantine Dimitrakakis[a] Flora Zagouri[b] Alexandra Tsigginou[a]
Spyros Marinopoulos[a] Theodoros N. Sergentanis[c] Antonis Keramopoulos[a]
George C. Zografos[c] Konstantina Ampela[a] Dimosthenis Mpaltas[a]
Christos Papadimitriou[b] Meletios-Athanassios Dimopoulos[b] Aris Antsaklis[a]

[a]Department of Obstetrics and Gynecology Alexandra Hospital,
[b]Department of Clinical Therapeutics, Alexandra Hospital,
[c]1st Propaedeutic Surgical Department, Hippocrateio Hospital, University of Athens, Greece

- 39 GİMK
- 39 premenopozal (gebelik ilişkisiz) meme ca

- Yaş, evre, grade, histolojik tip, östrojen reseptörü, progesteron reseptörü, c-erbB-2, KT, RT, Hormon terapisi, Trastuzumab kullanımı karşılaştırıldığında anlamlı fark yok.
- Relaps durumuna bakıldığında anlamlı fark bulunmuş.

Relaps yeri, n (%)	GİMK	Premenapozal Meme Ca
YOK	12 (30.7)	29 (74.4)
KEMİKLER	3 (7.7)	3 (7.7)
VİSSERAL	21 (53.9)	5 (12.8)
LOKAL BÖLGESEL	3 (7.7)	2 (5.1)

$p < 0.001$

McCready *et al. Breast Cancer Research* 2014, **16**:R2
http://breast-cancer-research.com/content/16/1/R2

Breast Cancer RESEARCH

RESEARCH ARTICLE Open Access

Pregnancy-associated breast cancers are driven by differences in adipose stromal cells present during lactation

Jessica McCready[1,2,6], Lisa M Arendt[1,2], Eugene Glover[1,2], Vandana Iyer[1,2], Jerrica L Briendel[1,2], Stephen R Lyle[3], Stephen P Naber[5], Daniel G Jay[4] and Charlotte Kuperwasser[1,2*]

www.fppt.info

- Gebelikte dolaşımda östrojen ve progesteron en yüksek seviyede
- Prolaktin gebelikte ve laktasyonda pik yapar.
  - Potent mitojen

Breast Cancer Research 2014, 16:R2

- Tüm bu hormonlar meme epitel proliferasyonu için güçlü modülatörler ve meme tümörü büyümesini hızlandırıcı etkiye sahip olabilir.

- Meme bezi mikroçevresinde hücresel kompozisyonda ve fenotipte meydana gelen lokal değişiklikler tümör gelişimini başlatabilir.

Breast Cancer Research 2014, 16:R2

- Stromal yağ hücreleri laktasyon süresince karsinom hücrelerinin gelişmesini ve anjiogenezisi destekler.

Breast Cancer Research 2014, 16:R2

- GİMK kompleks bir hastalıktır
- Sitemik ve lokal faktörler patobiyolojide etkilidir.
- Laktasyondaki stromal değişiklikler etyoloji ve patogenezde önemli rol oynar.

Breast Cancer Research 2014, 16:R2

REFERANSLAR

www.fppt.info

Breast Carcinoma in Pregnant Women

Assessment of Clinicopathologic and Immunohistochemical Features

Lavinia P. Middleton, M.D.[1]
Mitual Amin, M.D.[1]
Karin Gwyn, M.D.[2]
Richard Theriault, D.O.[2]
Aysegul Sahin, M.D.[1]

[1] Department of Pathology, The University of Texas M. D. Anderson Cancer Center, Houston, Texas.

[2] Department of Breast Medical Oncology, The University of Texas M. D. Anderson Cancer Center, Houston, Texas.

CANCER September 1, 2003 / Volume 98 / Number 5

Breast Carcinoma Presenting During or Shortly After Pregnancy and Lactation

Sami Shousha, MD, FRCPath

(*Arch Pathol Lab Med.* 2000;124:1053–1060)

EJSO (2005) 31, 232-236

ELSEVIER

Available online at www.sciencedirect.com

SCIENCE DIRECT®

EJSO
the Journal of Cancer Surgery
www.ejso.com

Breast cancer diagnosed during pregnancy and lactation: biological features and treatment options

O. Gentilini[a,*], M. Masullo[b], N. Rotmensz[c], F. Peccatori[d], G. Mazzarol[b], A. Smeets[a], S. Simsek[a], S. De Dosso[d], P. Veronesi[a], M. Intra[a], S. Zurrida[a], G. Viale[b], A. Goldhirsch[d], U. Veronesi[e]

The Journal of Clinical Investigation RESEARCH ARTICLE

Cyclooxygenase-2–dependent lymphangiogenesis promotes nodal metastasis of postpartum breast cancer

Traci R. Lyons,[1,2] Virginia F. Borges,[1,2,3] Courtney B. Betts,[1,2] Qiuchen Guo,[1,2] Puja Kapoor,[1] Holly A. Martinson,[1,2] Sonali Jindal,[1,2] and Pepper Schedin[1,2,3]

[1]Department of Medicine, Division of Medical Oncology, and [2]Young Women's Breast Cancer Translational Program, University of Colorado Anschutz, Aurora, Colorado, USA.

[3]University of Colorado Cancer Center, Aurora, Colorado, USA.

Mechanism and preclinical prevention of increased breast cancer risk caused by pregnancy

Svasti Haricharan[1,2†], Jie Dong[2†], Sarah Hein[1,2], Jay P Reddy[1,2], Zhijun Du[2], Michael Toneff[1,2], Kimberly Holloway[2], Susan G Hilsenbeck[2], Shixia Huang[1], Rachel Atkinson[3], Wendy Woodward[4], Sonali Jindal[5,6], Virginia F Borges[5,6], Carolina Gutierrez[2], Hong Zhang[7], Pepper J Schedin[5,6,8], C Kent Osborne[2], David J Tweardy[9], Yi Li[1,2*]

The Breast 23 (2014) 19–25

Contents lists available at ScienceDirect

The Breast

journal homepage: www.elsevier.com/brst

Original article

Preliminary monocentric results of biological characteristics of pregnancy associated breast cancer

Silvia Michieletto [a,*], Tania Saibene [a], Laura Evangelista [b], Franco Barbazza [a], Raffaello Grigoletto [a], Giovanna Rossi [c], Cristina Ghiotto [c], Fernando Bozza [a]

[a] *Surgery Oncology Unit, Istituto Oncologico Veneto IOV – IRCCS, Padova, Italy*
[b] *Radiotherapy and Nuclear Medicine Unit, Istituto Oncologico Veneto IOV – IRCSS, Padova, Italy*
[c] *Oncology 2 Unit, Istituto Oncologico Veneto IOV – IRCCS, Padova, Italy*

VOLUME 32 · NUMBER 3 · JANUARY 20 2014

JOURNAL OF CLINICAL ONCOLOGY

Prognosis of Women With Primary Breast Cancer Diagnosed During Pregnancy

Available online at www.sciencedirect.com

ScienceDirect

EJSO 34 (2008) 837–843

EJSO
the Journal of Cancer Surgery

www.ejso.com

Review

Breast cancer during pregnancy: A mini-review☆

I. Navrozoglou [a,*], T. Vrekoussis [a], E. Kontostolis [a], V. Dousias [a], S. Zervoudis [b], E.N. Stathopoulos [c], O. Zoras [d], E. Paraskevaidis [a]

[a] *Department of Obstetrics and Gynecology, Faculty of Medicine, University Hospital of Ioannina, 45100 Ioannina, Greece*
[b] *Lito Maternity Hospital, Athens, Greece*
[c] *Department of Pathology, Faculty of Medicine, University of Crete, Greece*
[d] *Department of General Surgery, Faculty of Medicine, University of Crete, Greece*

TEŞEKKÜR EDERİM…

www.fppt.info

www.fppt.info